

Review Article

Mammary Gland Tumours in the Dog, a Spontaneous Tumour Model of Comparative Value to Human Breast Cancer

Kabiru Sahabi, Sujey Kumar Rajendren, Jia Ning Foong and Gayathri Thevi Selvarajah*

Department of Veterinary Clinical Studies, Faculty of Veterinary Medicine, Universiti Putra Malaysia, 43400 UPM Serdang, Selangor, Malaysia

ABSTRACT

Mammary gland tumours are the most common neoplasia diagnosed in the female dog. These tumours occur spontaneously or naturally as in humans, 50% of which are commonly diagnosed as malignant. Metastasis to other tissues especially the lung is a common cause of death in these dogs. Treatment of canine mammary gland tumours (CMT) involves mainly surgical resection with wide margin followed by chemotherapy with cytotoxic drugs for those with lymph node and distant metastasis. With the dog continuously described as a very suitable and valuable large animal model of human breast cancer, it becomes very obvious that CMT can be a model to further understand the biology of cancer as well as screening for new therapeutic agents that could be used to treat human breast cancer and CMT more effectively. This review focuses on research work that has been done on CMT over the past years, describing the epidemiology, diagnostics and recent advances in therapy for CMT as well as discussing the significance of the dog CMT as spontaneous animal model for human breast cancer.

Keywords: Cancer biology, dog model, histopathology, human breast cancer, mammary tumours

ARTICLE INFO

Article history:

Received: 18 July 2017

Accepted: 30 November 2017

E-mail addresses:

kabirukalgo@gmail.com (Kabiru Sahabi)

r.sujeykumar@gmail.com (Sujey Kumar Rajendren)

jnfoong@live.com.my (Jia Ning Foong)

gayathri@upm.edu.my (Gayathri Thevi Selvarajah)

* Corresponding author

INTRODUCTION

In mammals, a modification of sweat gland results in the formation of the mammary gland, consisting of a network of ducts that are surrounded by adipose-rich fibrovascular stroma (Santos, Marcos, & Faustino, 2010; Sorenmo, Rasotto,

Zappulli, & Goldschmidt, 2011). In the canine species there are seven to 16 duct openings on each teat that extend to form a lobe (independent functional unit) of the canine mammary gland. In most dogs, five pairs of mammary glands

develop, but in some, it can occasionally range from four or six pairs (Sorenmo et al., 2011). The five pairs of glands include a cranial thoracic, caudal thoracic, cranial abdominal, caudal abdominal, and inguinal (Figure 1).

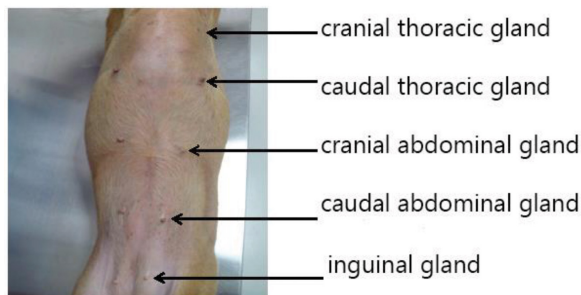


Figure 1. Anatomic positions of the five canine mammary glands

Canine Mammary Gland Tumour

A mammary tumour is an abnormal growth of tissue originating in the mammary gland. The tumour could be benign or malignant involving teats and glands that extend from the cranial thoracic to the inguinal of both sides of the midline. Mammary gland tumours are the most common neoplasia diagnosed in the female dog, accounting for up to 50% of all neoplasms diagnosed (Egenvall et al., 2005; Kelsey, Moore, & Glickman, 1998; Sahabi, Selvarajah, Noordin, Sharma, & Dhaliwal, 2015; Zuccari, Castro, Gelaleti, & Mancini, 2011). Like other tumours, canine mammary gland tumours occur spontaneously or naturally as in humans (Andrade, Figueiroa, Bersano, Bissacot, & Rocha, 2010). Fifty percent of CMT

are diagnosed as malignant according to reports from other geographical locations (Benjamin, Lee & Saunders, 1999; Dhami, Tank, Karle, Vedpathak, & Bhatia, 2010; Klopffleisch, Lenze, Hummel, & Gruber, 2011a). Metastasis to other tissues especially the lungs and lymphatics are common causes of death in the affected dogs (Rasotto, Zappulli, Castagnaro, & Goldschmidt, 2012).

Prevalence

The prevalence of canine mammary gland tumours (CMT) reported varies between dog populations. A high prevalence of more than 70% have been reported (Benjamin et al., 1999) in Colorado, United States of America (USA), in a life-span observation study involving 672 female beagles that

were experimentally exposed to radiation. An incidence of 51% per year for CMT in clinical cases in the USA has been reported Kelsey et al. (1998). In Sweden, a study was conducted involving a population of more than 80,000 insured female dogs and the incidence of CMT was reported to be 111 dogs per 10,000 dog year at risk (DYAR) (Egenvall et al., 2005). In clinical reports on CMT, the incidence reported from Europe ranges from 26.5% to 70% (Merlo et al., 2008; Valenčáková-Agyagosová & Ledecký, 2011). An incidence of 205 cases/100,000 dogs/year in the United Kingdom was also reported by Dobson, Samuel, Milstein, Rogers, & Wood (2002). In India, the prevalence of CMT was reported to be 24.3% to 39.9% (Dhami et al., 2010; Srivastava, Sharma, & Singh, 2009). In Malaysia, Sahabi et al., 2015 reported a prevalence of 39% for CMT among all neoplasia cases diagnosed in the pathology laboratory of the Faculty of Veterinary Medicine, Universiti Putra Malaysia, from 2006 to 2012. In a survey of tumours of domestic animals in South Africa, over a 40-year period, CMT was grouped under genital tract tumours in female dogs. The genital tract tumours make up 10.2% of the tumours affecting dogs and the CMT subgroup make up 80% of the genital tract tumours (Bastianello, 1983). At the time of diagnosis, a range between 52% to 86% of the mammary gland tumours in the dog have been reported as malignant (Klopfleisch, Lenze, Hummel, & Gruber, 2011b; Zuccari et al., 2008).

Aetiopathogenesis and Risk Factors

Hormonal Influence. As a bitch grows, mammary stem cell differentiation into ductal, alveolar and myoepithelial cells is regulated by hormones. Oestrogen is involved in the proliferation of the duct while progesterone is involved in the development of alveoli in the mammary gland of animals (Toniti, Buranasinsup, Kongcharoen, Puchadapirom, & Kasorndorkbua, 2009). At maturity, the release of oestrogen initiates mammary gland development, which is completed during and after pregnancy by progesterone and prolactin respectively (Sorenmo et al., 2011). The activity of progesterone peaks during pregnancy and the diestrous phase of the oestrous cycle in the intact bitch, resulting in the development of lobules and ducts lined by multiple layers of epithelium. Prolonged diestrous (prolonged progesterone activity) and exposure to progestagens (progesterone based contraceptives) have been shown to induce CMT development (Gräf & Etreby, 1978). The activity of oestrogen receptors is a major stimulator of cell proliferation in mammary epithelium, and has a close physiological association with progesterone receptor expression (Klopfleisch et al., 2011c). One of the most important causes of mammary gland tumour development in dogs is early exposure to ovarian hormones (Sorenmo et al., 2011). Endocrine aetiology of canine mammary tumour is well-defined, with non-spayed (intact) bitches having four times higher risk than bitches spayed before two years of age (Queiroga, Raposo, Carvalho, Prada, & Pires (2011).

Immunohistochemical studies have identified oestrogen and progesterone receptors in benign and malignant tumours, which strongly points to a hormonal cause (Queiroga et al., 2011). Variable proportions of oestrogen receptors (ER) in malignant and benign tumours have been demonstrated by immunohistochemical and biomedical methods and its presence has been associated with a favourable prognosis (Martin De Las Mulas et al., 2004). Two isoforms of the oestrogen receptors are known - oestrogen receptor alpha (ER α) and oestrogen receptor beta (ER β), with the former being the major oestrogen receptor (Balfe et al., 2004). Canine mammary tumour progression from benign to malignant is related to steroid dependency, as receptors of oestrogen and progesterone were expressed in 70% benign and 50% malignant tumours (Philibert et al., 2003). Using immunohistochemistry, it was revealed that ER β -positive tumours were largely more benign than malignant (Martin De Las Mulas et al., 2004). Generally ER positive CMT and more differentiated compared to ER negative CMT (MacEwen, Patnaik, Harvey, & Panko, 1982)

Age. Age is said to be one of the very important factors that influence the risk of canine mammary gland tumour development. Research carried out in a large closed beagle colony showed that mammary neoplasia occurs mainly in adult dogs (Taylor et al., 1976). According to the same study, the incidence rate of CMT remained low in dogs up to seven

years of age (the earliest cancer occurred at seven years of age). At eight years of age, a sharp rise in the incidence was observed, which remained high as the age increases. In a study by Sahabi et al., 2015, the mean age of occurrence of CMT in the dog population was 8.66 years, while the median age was nine years. Moreover, age of the dogs was significantly associated with CMT development in the dogs. No mammary tumour was seen in a population of over 500 male dogs in the said study. The earliest age for mammary gland tumour in dogs however, may vary between breeds according to the natural life span. A range of eight to 11 years is reported as the age of dogs affected by CMT (Sorenmo et al., 2011). A progressive increase in the incidence of mammary gland tumour was observed in dogs from three to nine years of age, after which the frequency declined and reached its lowest at 15 years (Mitchell, De la Iglesia, Wenkoff, Van Dreumel, & Lumb, 1974).

Breed Predisposition. Mammary gland tumour is more common in toy and miniature breeds (Itoh, et al., 2005; Mitchell et al., 1974; Philibert et al., 2003; Sorenmo et al., 2011; Zatloukal, Lorenzova, & Tichý, 2005). According to a study carried out in Sweden by Egenvall et al. (2005) involving more than 80,000 insured female dogs, the incidence of CMT varied between breeds. The English springer spaniel had incidence of 319 dogs per 10,000 DYAR, while the Rough Collie had an incidence of five dogs in 10,000 DYAR. Poodle was the shown to

be the most susceptible breed representing 25% of 720 dogs with mammary gland tumour cases (Mitchell et al., 1974). Larger breeds such as Afghan Hound, Brittany Spaniel, English Setter, German Shepherd and Pointer are also at an increased risk of mammary gland tumour development (Sorenmo et al., 2011). Pure breed dogs are reported to have a higher representation in CMT compared to mixed breed (Perez Alenza, Peña, Del Castillo, & Nieto, 2000; Philibert et al., 2003; Sahabi et al., 2015; Zatloukal et al., 2005).

Obesity. Mammary gland tumour development in dogs has been linked to obesity. Dogs that are obese at one year of age or if they are obese at one year before the diagnosis of CMT, have a higher prevalence of mammary gland tumour than those that do not (Perez Alenza et al., 2000; Philibert et al., 2003). A decreased risk of developing mammary gland tumour in dogs is associated with poor body condition at nine to 12 months of age, but interestingly enough, obese animals of the same age in the study did not have a higher risk of mammary gland tumour development (Sorenmo et al., 2011). In another study, there was little or no association between adult body conformations with the risk of CMT in intact or spayed bitches (Sonnenschein, Glickman, Goldschmidt, & McKee, 1991). Obesity increases the risk of breast cancer development in postmenopausal women, due to increasing local and free circulating oestrogen. Obesity in dogs may influence the development

of mammary gland tumour via the same mechanisms (Sorenmo et al., 2011). A high intake of beef, pork and a decreased consumption of chicken has been linked to a high incidence of mammary gland tumour in dogs (Perez Alenza et al., 2000). The development and biological behaviour of mammary gland tumour are believed to be influenced by body fat content, as Philibert et al. (2003) reported a shorter survival of obese dogs with mammary gland tumour, compared to those with poor body condition at nine to 12 months of age.

Clinical Presentation

Typically, the owner of the dog will present their pet dogs to the veterinarian with a primary complaint of lump(s) observed on the mammary gland(s) (Figure 2). Depending on the tumour type, and / or time taken from the start of tumour development to the time of presentation to the veterinarian, other clinical signs such as ulceration around the affected gland(s), anorexia, pyrexia, emaciation, change in gait, signs of pain, in some cases, anaemia and other signs of systemic illnesses can occur. The caudal abdominal and inguinal mammary glands are most commonly affected as compared to other glands in the dog (Sahabi et al., 2015; Sorenmo et al., 2011). This has been suggested to be attributable to a more abundant glandular tissue and the larger size and the longer time of secretory activity in the abdominal and inguinal glands (Mitchell et al., 1974). Furthermore, low incidence of mammary gland tumour in male dogs could be due

to the absence of the influence of ovarian hormones (oestrogen and progesterone) on the mammary tissue, and a smaller amount of susceptible tissue, which are both characteristics in female dogs (Taylor et

al., 1976). A dog could have more than one tumour in its mammary gland(s), freely movable or fixed, presented with ulcerative surface, small or large (Mitchell et al., 1974; Sorenmo et al., 2011).

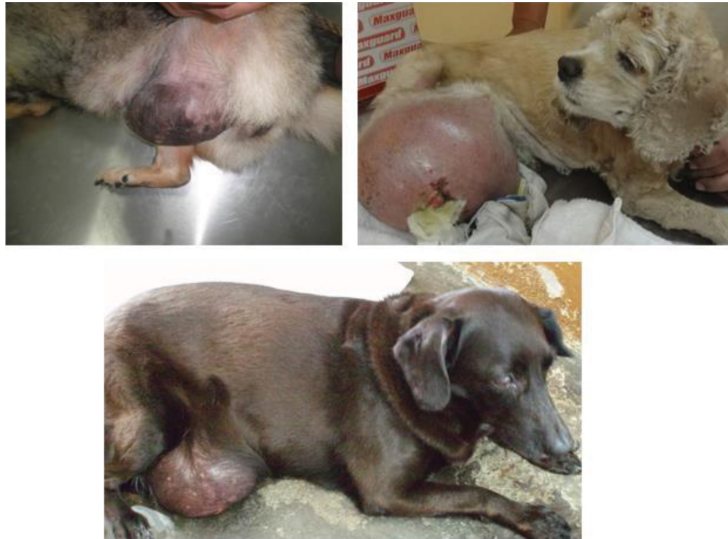

Figure 2. Dogs with spontaneously developed natural mammary gland tumours

Metastasis

Metastasis is when a cell from a primary tumour leaves the tumour, gets into systemic circulation, and invades a distant site to establish a secondary tumour (Woodhouse, Chuaqui, & Liotta, 1997). Metastasis through the haematogenous route to the lungs has been found to be a common cause of deaths in dogs with malignant CMT (Klopfleisch et al., 2011a; Rasotto et al., 2012). Another route of

metastasis is via the lymphatic system to the draining lymph node, from where it will invade other tissues of the body (Rasotto et al., 2012). For these reasons, staging of the disease in a human breast cancer patient or a dog mainly involves examination of the lungs and regional lymph nodes for abnormalities and to seek possible evidence of metastasis to other body systems from the examination (Table 1).

Table 1
Sites for metastasis in dogs with mammary gland tumours

<i>Organ/tissue of metastasis</i>	<i>References</i>
Lymph node(s)	(Kim et al., 2011; Sorenmo et al., 2000)
Lung	(Sorenmo et al., 2011)
Liver, kidney and spleen	(Kim et al., 2011; Valenčáková-Agyagosová & Ledecký, 2011)
Brain, eye, skin, bone, heart	(Kim et al., 2011; Valenčáková-Agyagosová & Ledecký, 2011)

Diagnostic Investigations

In any condition, diagnosis starts with history taking and obtaining signalment of the dog including information on age, breed, neuter status, breeding information, use of exogenous hormones, history of trauma and vaccinations. Physical examination should include examinations that do not focus on the affected mammary glands but also other systems in the body to detect presence of concurrent illnesses. During examination of the tumour, the following should be noted: size, site, number of affected glands and the surrounding tissues, whether they are sessile, movable or ulcerated. The regional lymph node(s) should be carefully palpated and examined to evaluate enlargements, which could be possible in cases of metastasis.

Differential diagnoses typical for masses such as hematoma, abscessation, cyst formation, granuloma or neoplasia / hyperplasia have to be included for masses involving the mammary glands. However, it is difficult to diagnose neoplasia just by observation of the masses, especially those with only a single gland affected. Canine mammary tumours can appear cystic, presented with infection and necrotic

tissue (pus) or even ulceration with active bleeding. Infections on the mammary tumour are relatively common because of the high possibility for the dog to lick or bite on the tumour; or contaminated with soil bacteria when the dog lies down.

Diagnostic Cytology. Fine needle aspiration (FNA) and diagnostic cytology has been described as a valuable diagnostic tool (Santos et al., 2013) (Figure 3). Although easy to perform, tumour classification is difficult, as tissue architecture is not available in FNA (Hellmén & Lindgren, 1989). Fine needle aspiration is very important in the initial stage of the diagnosis as it helps to exclude differential diagnoses such as mastitis, abscessation and hyperplasia (Cassali et al., 2011), with an accuracy rate of 79% reported (Hellmén & Lindgren, 1989). When there is ulceration or discharge present from the affected teat, an impression smear of the ulcerated site or discharge can be useful specimen to facilitate diagnostic cytology. In such cases, there is no need to perform an active FNA or incisional biopsy sampling.

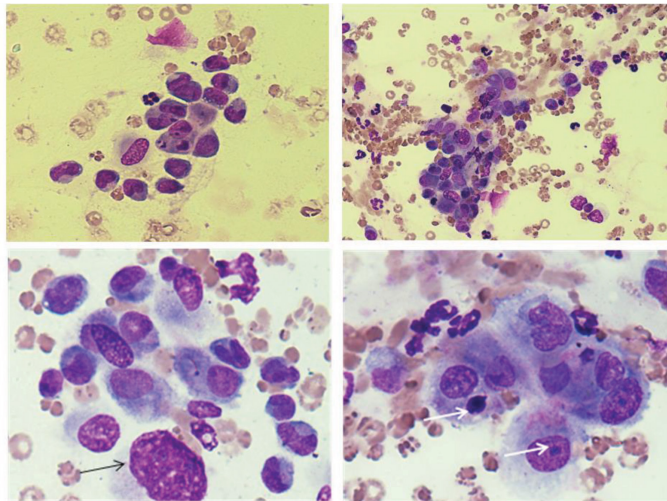


Figure 3. Impression smear cytology of an ulcerated tumour

The figure shows an ulcerated tumour of a mammary gland in a dog for cytology showing marked cell size variation (anisocytosis), irregular nuclear-cytoplasmic ratio, bare nuclei (black arrow) and irregular nuclear size -anisokaryosis (white arrows). The two images above are magnified 400 times while the two below are magnified x1000.

Diagnostic Imaging. There are many different diagnostic imaging modalities available in veterinary practice including radiography, magnetic resonance imaging (MRI) and computed tomography (CT). Radiography is widely available even in small local veterinary practices, which can be incorporated to help determine the prognosis of disease. However, this imaging method is not sensitive to evaluate metastasis to lymph nodes or other soft tissues. For the dog with mammary gland tumour, thoracic radiography is

most essential for evaluation of possible pulmonary metastasis. Ideally, three thoracic radiographic views are recommended for this purpose - the ventro-dorsal, right lateral and left lateral views (Cassali et al., 2011). Diagnostic ultrasonography can be performed to evaluate the internal soft tissue organs for possible metastasis and even combined with FNA guided by ultrasonographic techniques to evaluate metastasis using cytology. Abdominal ultrasonography is used when metastasis to other anatomical sites is suspected during physical examination, or if haematological abnormalities are noted (Cassali et al., 2011; Matos, Baptista, Gärtner, & Rutteman, 2012; Novosad, 2003). Other advanced imaging modalities such as MRI and CT have been used to detect micrometastasis in clinical cases but their usefulness for the general practitioners and in staging of the affected dogs are limited. Computed tomography (CT) is a sensitive technique

that is able to detect micro-metastasis to the lungs of less than six mm in diameter (Cassali et al., 2011; Matos et al., 2012). Computed tomography may also be used to monitor response to therapy (Matos et al., 2012).

Histopathology. Histopathology is the method of choice and has been described as the “gold standard” to achieve an accurate diagnosis for CMT (Cassali et al., 2011; Rasotto et al., 2012). It allows for the study of the histopathology characteristics of the tumour such as the mitotic index, differentiation, degree of pleomorphism, amount of necrosis, and invasion of neoplastic cells into adjacent blood vessels and lymphatic and the evaluation of margins of the excised tumour (Cassali et al., 2011). Routine histopathology is performed using hematoxylin and eosin staining protocols, which most of the time are sufficient

for diagnosing CMT. However, selected subtypes or histopathology variants of CMT could be more difficult to diagnose using routine staining and require special staining or immunohistochemistry techniques for an accurate diagnosis (Matos et al., 2012).

World Health Organization (WHO), in 1974, presented the first international histological classification of tumours of domestic animals and in 1999, a modification (Table 2) of the classification system was published (Hampe & Misdorp, 1974; Misdorp, Else, & Hellmen, 1999). These were the basis for the classification of tumours in domestic animals including mammary gland tumours of the dog. Recently, some modifications to the classification systems for canine mammary tumours were proposed because of the need to incorporate newly described histologic subtypes of CMT (Goldschmidt, Peña, Rasotto, & Zappulli, 2011).

Table 2
The World Health Organization (WHO) classification (1999) of canine mammary gland tumours

<i>Tumour type</i>	<i>Tumour sub-type</i>
1. Malignant tumours	1.1 Non-infiltrating (in situ) carcinoma
	1.2 Complex carcinoma
	1.3 Simple carcinoma
	1.3.1 Tubulopapillary carcinoma
	1.3.2 Solid carcinoma
	1.3.3 Anaplastic carcinoma
	1.4 Special types of carcinomas
	1.4.1 Spindle cell carcinoma
	1.4.2 Squamous cell carcinoma
	1.4.3 Mucinous carcinoma
	1.4.4 Lipid rich carcinoma
	1.5 Sarcoma
	1.5.1 Fibrosarcoma
	1.5.2 Osteosarcoma
	1.5.3 Other sarcomas
	1.6 Carcinosarcoma
	1.7 Carcinoma or sarcoma in benign tumour

Table 2 (*continue*)

<i>Tumour type</i>	<i>Tumour sub-type</i>
2. Benign tumours	2.1 Adenoma 2.1.1 Simple adenoma 2.1.2 Complex adenoma 2.1.3 Basaloid adenoma 2.2 Fibroadenoma 2.2.1 Low-cellularity fibroadenoma 2.2.2 High-cellularity fibroadenoma 2.3 Benign mixed tumour 2.4 Duct papilloma
3. Unclassified tumours	
4. Mammary hyperplasia and dysplasia	4.1 Ductal hyperplasia 4.2 Lobular hyperplasia 4.2.1 Epithelial hyperplasia 4.2.2 Adenosis 4.3 Cysts 4.4 Duct ectasia 4.5 Focal fibrosis (fibrosclerosis) 4.6 Gynecomastia

A brief description of the histopathology features of the types of canine mammary gland tumours (Cassali et al., 2011; Goldschmidt et al., 2011) is described below.

Benign Mammary Gland Tumours

Adenoma. This type of tumour is composed of well differentiated epithelial or myoepithelial cells. It is classified as simple tubular type. The solid nodes are composed of fusocellular cells and are called myoepitheliomas. It is a rare tumour in dogs.

Complex Adenomas or Adenomyoepitheliomas. The origin of this tumour is from continuous proliferation of myoepithelial and epithelial cells, without

forming myxoid matrix. It is characterised by having a capsule, no necrosis, atypia and low mitosis.

Basaloid Adenoma. This type of tumour consists of uniform cords on basaloid monomorphic epithelial cells nest. The cells of the periphery are arranged side-by-side manner and are oriented against a thin basal lamina. In most cases the tumours are small.

Fibroadenoma. This type of tumour originates from the proliferation of stromal and epithelial elements. Two sub types are described as: (1) pericanicular fibroadenoma (the stroma surrounds the epithelium) and (2) intracanicular fibroadenoma (the stroma compresses and deforms the epithelium).

Benign Mixed Tumour. This type of tumour consists of proliferated cells that appear either fusiform or stellate, morphologically resembling mesenchymal cells and epithelial components, producing adipose tissue and/or cartilage and/or bone, sometimes with fibrous tissue. The cells are sometimes embedded in abundant myxoid matrix. There is some level of pleomorphism and atypia. It is the most common benign tumour in dogs.

Ductal Papilloma. This type of tumour is lobed or ramified in a distended duct. There is proliferation of the epithelium of ducts on a fibro-vascular axis. Cellular atypia is evident on the epithelium, and nuclear hyperchromasia. There is minimal mitotic activity and the epithelium is distributed as a single layer on a layer of myoepithelial cells.

Malignant Mammary Gland Tumours

Ductal Carcinoma In-situ. This is the most common of the two types of carcinoma in-situ, the other type is lobular ductal carcinoma in-situ. It is often associated with invasive canine mammary carcinomas. The tumour develops in the extra- or intra-lobular ducts. DCIS is characterised by the proliferation of epithelial cells in more than two ductal units in one histological section. The cellular architecture of the cells is atypical, characterised by connecting bridges in the ductal lumen. There is also polarisation of epithelial cells in a layer associated with another continuous layer comprising myoepithelial cells. There are micro-calcifications seen in the ductal lumen.

Lobular Carcinoma In-situ. In this type of tumour, epithelial proliferation causes the filling and expansion of the terminal lobular units. About 50% of the lobe is affected and the lumen is completely lost, but the basement membrane is maintained. The cells have the same shape, with small and spherical nuclei. The nuclei are small with discrete and uniform nucleoli. There is noticeable invagination of the cytoplasmic membrane due to a single vacuole around the nucleus.

Carcinoma in a Mixed Tumour. Mixed tumours exhibit a complex histological pattern, having cellular components from epithelial and mesenchymal origin. Some of the cells can turn malignant, giving rise to carcinoma in mixed tumours. Carcinoma in mixed tumours composed of nodules or foci of highly pleomorphic epithelial cells with atypical mitoses, arising in benign mixed tumours.

Complex Carcinoma or Malignant Adenomyoepitheliomas. This tumour is made up of epithelial and myoepithelial cells proliferation. However, myxoid matrix is not evident. Other features include atypia, necrosis, and absence of a capsule and high mitotic activity.

Papillary Carcinoma. Papillary aborescent epithelial proliferation with a central fibrovascular stroma characterises this tumour. These lesions are classified as papilloma, carcinoma in-situ in papilloma, papillary carcinoma in-situ, invasive and

non-invasive papillary carcinomas. In benign tumours, neoplastic papillae that have within them myoepithelial cells could be observed between basement membrane and the epithelial cells. This characteristic is not seen in the malignant variant.

Tubular Carcinoma. Predominantly tubular arrangement of the proliferated epithelial cells qualifies this type of tumour. The amount of stroma is variable. With or without necrosis, peritumoural lymphocytes can be seen. The rate of tissue and vessel invasion is high in these tumours.

Solid Carcinoma. This is a common cancer of dogs that is usually seen when the tumour has stayed for a long time without surgical intervention. On histopathology, the epithelial cells are solidly arranged in chords, sheets or clusters. The cells are not differentiated, with small hyperchromatic nuclei with a high mitotic index. In some cases, the cells will exhibit vacuolated cytoplasm. There is variable amount (small to moderate) of stroma and areas of necrosis.

Micropapillary Carcinoma. Microscopically, this tumour is characterised by the presence of cystic spaces that look like lymphatic vessels distributed within the mammary gland tissue. Within the spaces, a micropapillary pattern which is morule like, is assumed by clusters of epithelial cells. The cytoplasm is eosinophilic and abundant. The nucleus is vesicular and pleomorphic with prominent nucleoli. Lymph node metastasis is common and the

mitotic index is variable. For confirmation, immunohistochemistry can demonstrate the epithelial membrane antigen which will be the form of micropapillary arrangement of the cells.

Invasive Lobular Carcinoma. This type of CMT shows small cells in a linear arrangement, which are non-polar and are uniform in size. The tumour is diffusely invasive with large amount of fibrous stroma. Solid foci may be formed by the tumour cells, containing mucin and having a signet appearance, or arranged around benign ducts in a parallel way.

Pleomorphic Lobular Carcinoma. First found in dogs in 2002, this tumour is a result of the dispersal of epithelial cells in the stroma, or an irregular outline of the cells in a linear pattern. The cytoplasm is abundant and eosinophilic with accentric and pleomorphic nuclei. Cytoplasmic vacuoles are sometimes seen.

Secretory Carcinoma. With fine needle aspiration biopsy (FNAB), the cells are round to oval and in the form of clusters. The nucleoli are fragmented and the chromatin is irregularly distributed. The cells have a clear and abundant cytoplasm with the nucleus pushed to the periphery by secretory vacuoles. Histopathologically, this tumour is seen as an infiltrative carcinoma, with the neoplastic cells having peripherally displaced nucleus by large vacuoles and a clear cytoplasm. The proliferation pattern could be solid and/or tubular with

eosinophilic spaces filled with secretion. In secretory carcinoma, the intracytoplasmic content of the cells is PAS positive.

Mucinous Carcinoma. The presence of abundant extracellular mucinous material characterises this tumour. It is also known as gelatinous carcinoma. The proliferated cells may form solid, tubular or papillary structure. Large amount of mucinous eosinophilic secretions fill the spaces in these structures. The secretion is also PAS positive in diastase and alcian blue. The accumulated mucin is mostly located in the intraductal structure. When the mucoid content leaks from the intraductal structure, it then becomes invasive mucinous carcinoma.

Lipid-rich Carcinoma. This tumour is uncommon in dogs and is characterised by an expansive growth. The stroma separates the nests and cords of neoplastic cells. The cytoplasm of the cells is vacuolated and the nuclei are round to flat. There may be peripheral displacement of the nucleus by vacuoles. When 80% of the tumour cells are lipid producing, the diagnosis is confirmed. The cells of this tumour are PAS negative.

Squamous Cell Carcinoma. This tumour is characterised by areas of squamous differentiation in the solidly arranged sheets and cords of tumour cells. Keratin pearls (keratin layers) are found in the centre of the more differentiated tumour. Invasion of the lymphatics in these tumours is not uncommon.

Spindle Cell Carcinoma. This tumour is not very common in dogs. On histopathology, there is presence of spindle cells in bundles or in a circular pattern. The cytoplasm of the cells appears eosinophilic and might be vacuolated. The nuclei could also be vacuolated with a fragmented chromatin. These features should be seen in at least 80% of the tumour section in order to confirm the diagnosis.

Anaplastic Carcinoma. This histologic sub type of CMT is highly aggressive with early metastasis and recurrence and is considered to have the worst prognosis. This tumour is diffusely infiltrative. The proliferating epithelial cells are large, atypical with linear outline. The stroma is loose, abundant and reactive, with individual cells invading it. The cells are also anaplastic, with one or two prominent nucleoli and chromatin fragmentation. The tumour has a high mitotic index with marked anisocytosis. Blood and lymphatic vascular structures invasion by neoplastic cells could be observed and one of the prominent features of this tumour is inflammation.

Fibrosarcoma. These tumours are malignant and are made up of fibroblasts with varying amounts of collagen. Collagen-producing spindle-shaped cells are arranged as reticular fibres form these tumours. Fibrosarcomas are among the most encountered mammary sarcomas in the dog.

Osteosarcoma. This sarcoma is characterised by the formation of bone and/or osteoid by the neoplastic cells. Osteosarcoma could occur as combined or non-combined (pure). The combined form has both osseous and cartilaginous malignant tissues. There is high mitoses and pleomorphism.

Carcinosarcoma. In the dog, the features of carcinosarcoma resemble those described in humans. The cut surfaces of these tumours are firm to bony with a clear delineation. The cells are epithelial-like and well delineated. The type of differentiation varies including solid, adeno, mucinous, anaplastic, squamous, and sarcomatous areas with fibroblastic, chondroblastic and osteomatous differentiation. When present, metastasis is of mixed type, sarcomatous or carcinomatous.

Other Sarcomas. Other sarcomas that could occur in the mammary gland include pure chondrosarcoma, haemangiosarcoma and liposarcoma. These are extremely rare and have similar features to those observed in other organs.

Blood and Urine Profile. Haematological abnormalities are often observed in dogs bearing mammary gland tumour. In human mammary carcinoma, thrombocytopenia might be used as prognostic indicator. In a study on 246 dogs with CMT, thrombocytosis, hypergammaglobulinaemia and neutropaenia were most obvious abnormalities (Lallo, Ferrarias,

Stravino, Rodriguez, & Zucare, 2016). Thrombocytosis has been linked with systemic inflammatory reaction which involves interleukin-1 beta and interleukin-6 which is abundant in mammary gland tumour (Lallo et al., 2016). Hypergammaglobulinaemia is due to acute or chronic inflammatory reaction going on at the mammary gland (Lallo et al., 2016). Some haematological changes can be due to paraneoplastic syndromes. Paraneoplastic syndromes are tumour related alterations in anatomical structure or function or both that take place further from the tumour (Bergman, 2012). Mammary gland carcinoma or adenocarcinoma can cause hypercalcaemia (Bergman, 2012). Hypercalcaemia is due to pathological bone resorption caused by the cytokines that induce osteoclast differentiation and activity. Parathyroid hormone-related protein (PTHrP) is one of the cytokine involved in osteoclast differentiation and activity. PTHrP is also secreted by normal mammary gland during lactation. Thus, in the case of mammary gland tumour the production of PTHrP will be high which leads to hypercalcaemia (DeMauro & Wysolmerski, 2005).

Urinalysis has no significant impact and is not able to provide prognostic value for dogs with CMT. However, there has been a study discussing the possibility of proteinuria development in dogs with mammary carcinoma (Crivellenti et al., 2016) which is caused by by-products from neoplastic cell's interaction with immune cells to form

complexes and trigger release of acute phase proteins which can cause glomerular damage (Crivellenti et al., 2016).

Figure 4 below shows some of the histopathology variants of CMT described in the literature.

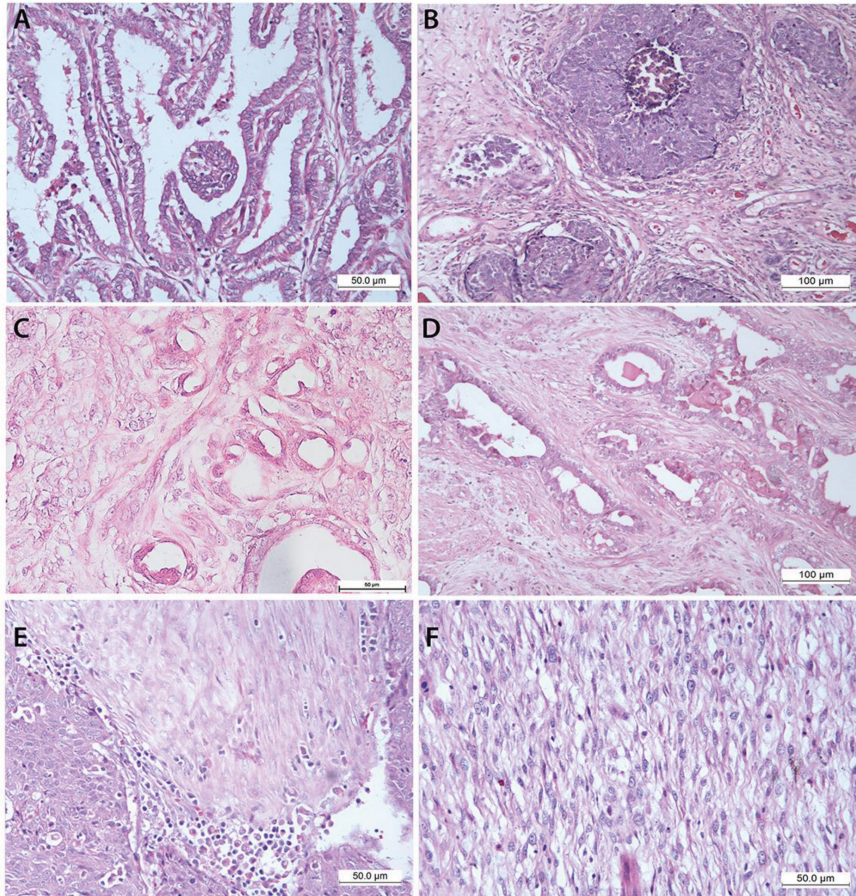


Figure 4. Some of the histologic subtypes of CMT

A is tubulopapillary carcinoma, B is solid carcinoma, C is squamous cell carcinoma, D is ductal carcinoma, E is anaplastic carcinoma and F is carcinosarcoma.

Staging of CMT

Canine mammary gland tumours are staged according to the TNM system,

namely, the tumour size, lymph node and metastasis (Matos et al., 2012; Sorenmo et al., 2011). Information about tumour size, lymph node involvement and presence of metastasis are needed to stage a CMT patient. The tumour with the largest diameter should be used for staging a CMT patient with more than one tumour. Fine

needle aspiration and subsequent cytology examination of the nearby draining lymph node should be performed if the lymph node is enlarged and palpable (Sorenmo et al., 2011). Thoracic radiography with at least three views should be performed to identify metastasis since lungs are the most common site of metastasis. However, abdominal radiography or ultrasonography can be performed if metastasis is suspected in the said anatomical location. Table 3 summarises the original WHO staging system (Owen, 1980) and the modified WHO staging system (Rutteman & Withrow, 2001; Sorenmo et al., 2011). Staging of CMT will facilitate record keeping and communication between clinicians on the patient's status. Furthermore, staging systems allow for comparison between patients with similar tumour burden, which is crucial when evaluating the effectiveness of new treatments (Sorenmo et al., 2011). Besides, staging of CMT correlates with the prognosis of the disease: an advanced stage confers a worse prognosis and a poor prognosis typically requires an escalation in therapy (Yamagami, Kobayashi, Takahashi, & Sugiyama, 1996). Thus, complete staging provides crucial prognostic information, which is subsequently implemented in the patient's treatment plan (Goldschmidt et al., 2011; Sorenmo et al., 2011).

In stage I CMT of small, non-invasive or well-differentiated tumours, surgery alone could be curative, while larger tumours with advancing stage and ill-

defined margins may require other forms of adjunctive therapies (Cassali et al., 2011; Sorenmo et al., 2011). Examples of adjunctive therapies include chemotherapy, hormonal therapy and radiotherapy. However, there is no established guidelines for treatment beyond surgery for CMT patients (Sorenmo, 2003).

In CMT patient, the best surgical plan involves removing all of the affected tissue with wide surgical margins (Novosad, 2003). Nodules or lumpectomy may be performed on singular, small sized tumours (about 0.5 cm), while larger and more aggressive tumours will require mastectomy (either simple, in block or radical mastectomy depends on the size of the tumour itself) (Cassali et al., 2011).

Adjuvant chemotherapy is recommended for CMT patients with metastasis condition (stage IV – V CMT), and, CMT patients diagnosed with solid carcinomas, micropapillary carcinomas, anaplastic carcinomas and carcinosarcomas even when lymph node or lung metastasis is not evident (Cassali et al., 2011; Novosad, 2003). Commonly used chemotherapy drugs include doxorubicin, 5-fluorouracil and cyclophosphamide, in which, doxorubicin is considered one of the most active agents for patients with advanced CMT staging (Sorenmo, 2003).

According to Sorenmo (2003), the development of most mammary gland carcinomas is oestrogen dependent and the majority of canine mammary gland carcinomas express oestrogen receptors (ER). Benign and well-differentiated

mammary gland tumours (stage I - III CMT) are often ER-positive and the dogs with ER-positive mammary gland tumour present a higher survival rate and are potential candidates for hormonal therapy whereas poorly differentiated and anaplastic mammary gland tumours (stage IV to V CMT) are usually ER-negative and will not respond well to hormonal therapy (Cassali et al., 2011; Ferreira, Bertagnolli, Cavalcanti, Schmitt, & Cassali, 2009; Sorenmo, 2003).

Staging of a CMT patient should be done regularly because it is also closely associated to the prognosis and survival expectation of the dog. Similar to other

solid tumour, dogs with advanced staging of CMT have poorer prognosis. For instance, dogs diagnosed with stage IV CMT (lymph node metastasis presence) have a shorter survival time compared to dogs with stage III CMT (without lymph node metastasis) (Matos et al., 2012; Sorenmo et al., 2011). Therefore, dogs diagnosed with a lower stage of CMT will have longer survival time. Canine mammary gland tumour classified as inflammatory carcinomas are highly aggressive and patient's survival time is typically less than one month (Clemente et al., 2013; Sorenmo, 2003).

Table 3
Staging system for canine mammary gland tumours

Stage	Original WHO Staging System (Owens, 1980)			Stage	Modified WHO Staging System (Rutteman & Withrow, 2001)		
I	T _{1a, b, c}	N ₀	M ₀	I	T1	N ₀	M ₀
	T ₀	N ₁	M ₀				
II	T _{1a, b, c}	N ₁	M ₀	II	T2	N ₀	M ₀
	T _{2a, b, c}	N ₁ or N _{1a}	M ₀				
III	T _{3a, b, c}	anyN	M ₀	III	T3	N ₀	M ₀
	anyT	anyN _b	M ₀				
IV	anyT	anyN	M ₁	IV	anyT	N ₁	M ₀
V	No Stage V			V	anyT	anyN	M ₁

T: primary tumour (a: not fixed; b: fixed to skin; c: fixed to muscle)
T₀: no evidence of tumour
T₁: <3cm maximum diameter (a, b, c)
T₂: 3-5cm maximum diameter (a, b, c)
T₃: >5cm maximum diameter (a, b, c)
T₄: any T, inflammatory carcinoma
N: regional lymph node status (a: not fixed; b: fixed)
Assessed by clinical examination or histopathology
N₀: no metastasis
N₁: metastasis ipsilateral lymph node (a, b)
N₂: metastasis bilateral lymph node (a, b)
M: distant metastasis
M₀: no distant metastasis
M₁: distant metastasis detected
^a Excluding inflammatory carcinoma

Histologic Grading of Canine Mammary Gland Tumours

Histologic malignant grade of tumour is a simple histological assessment done on Haematoxylin and Eosin (H&E) stained tissue slides that is used to determine the extent of differentiation of solid tumours. There is no specific grading system for CMT, however, the “Elston and Ellis grading method” for human breast adenocarcinoma has been applied on CMT and found to be associated with prognosis in the affected dogs (Karayannopoulou, Constantinidis, & Dessiris, 2005). The grading method evaluates the tubule formation in the tumour tissue, nuclear pleomorphism and mitosis per 10 high power field (Goldschmidt et al., 2011). The tubule formation is scored 1, 2 or 3, depending on whether the tubule formation in the tissue is more than 75%, 10-75% and less than 10% respectively. The nuclear pleomorphism is scored 1, 2 or 3, depending on whether the nuclear size is uniform, moderately variable shape and size and marked variation in size respectively. The mitoses criteria is scored 1, 2 or 3 if there are 0 to 9 mitotic figures, 10 to 19 mitotic figures and more than 20 mitotic figures per 10 high power fields respectively. If the total score of a tissue is 3 to 5, it is scored as grade 1 (low grade). If the score is 6 to 7, it is scored as grade 2 (intermediate grade). If the total score of a tissue is 8 to 9, it is scored grade 3 (high grade).

Therapeutic Modalities

Surgery. Surgical excision is the recommended therapeutic procedure for

the treatment of CMT (Cassali et al., 2011; Novosad, 2003), and is also the most widely used form of treatment (Novosad, 2003). In the absence of metastasis, surgery has the highest chance of curing the condition (Cassali et al., 2011). In addition to improving survival time and quality of life, by eliminating pain and discomfort, surgically excised tumours allow for more in-depth examination by histopathology (Cassali et al., 2011). The extent and type of surgery to be performed is determined by the characteristics of the tumour. The size and location of the lesion, extent of the disease and lymphatic drainage are all considered in the choice of surgical procedure to be performed. Nodules or lumpectomy may be done on small sized tumours (about 0.5 cm), while larger and more aggressive tumours require mastectomy (simple, in block or radical) (Cassali et al., 2011). While some researchers recommend the excision of the whole mammary chain to prevent recurrence, some argue that there is no difference in recurrence and survival of these patients compared to those that undergo local excision (Novosad, 2003). In small, non-invasive or well demarcated tumours, surgery alone could be curative, while larger tumours with ill-defined margins may require other forms of adjunctive therapies (Cassali et al., 2011). Figure 5 shows a dog with recurrent or regrowth of invasive mammary carcinoma after mastectomy, due to high grade of the tumour and poor surgical margins.

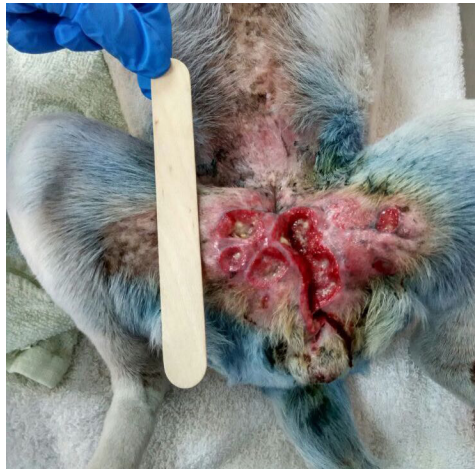

Figure 5. A dog presented with regrowth of invasive mammary adenocarcinoma after initial mastectomy due to high grade of the tumour and poor surgical margins

Chemotherapy. Although chemotherapy is incorporated into the treatment of CMT, its efficacy is not fully established in veterinary practice (Novosad, 2003). Doxorubicin is among the common cytotoxic drug used in the treatment of CMT. It has been shown to have some antitumour effect on CMT cell lines in-vitro (Novosad, 2003). Doxorubicin can be used alone or in combination with cyclophosphamide (Cassali et al., 2011). Carboplatin and Cisplatin can also be used in the treatment of CMT, although there is still the need to establish the true efficacy of each of these drugs in the treatment of CMT (Cassali et al., 2011). Recently, gemcitabine has been used in the treatment of CMT, usually in a combination with a platinum-based drug such as Carboplatin (Cassali et al., 2011).

Anti-Inflammatory. In dogs with inflammatory mammary carcinoma, treatment with piroxicam (a non-steroidal anti-inflammatory drug) produce a positive clinical response and improved quality of life, with a longer mean survival time compared to the mean survival time of dogs treated with doxorubicin (Souza , Toledo-piza, Amarin, Barboza, & Tobias, 2009). The study also reported that 100% of the dogs treated with doxorubicin-cyclophosphamide chemotherapy combination died within one month of treatment, but the piroxicam treated dogs had a mean survival time of 174 days. Surgery is not commonly recommended in dogs with inflammatory mammary carcinoma, but drugs that can reduce pain, in association with some anti-cancer drugs are recommended and firocoxib has been recently proposed as a palliative treatment (Cassali et al., 2011).

Hormonal Therapy. Hormonal therapy is employed in human practice in patients with oestrogen receptor-positive (ER⁺) breast tumours (Novosad, 2003). Such ER⁺ tumour patients have a favourable prognosis (Martin De Las Mulas et al., 2004) and are the targets for hormonal therapy in breast cancer in humans and mammary gland tumours in dogs (Cassali et al., 2011). Tamoxifen (an antiestrogenic agent) has been suggested in the treatment of spayed dogs with ER⁺ CMT, although side-effects such as pyometra, mammary masses/secretions and death have been observed in the study involving 20 healthy dogs (10 intact and 10 spayed). A controlled dose for up to 120 days is suggested with assessment and control of side effects (Tavares et al., 2010). The efficacy of hormonal therapy is ambiguous in CMT, as conflicting results of success and failure have been reported (Novosad, 2003).

Palliative Radiation Therapy. Radiation therapy is not commonly used as primary therapy in the management of CMT, except in non-resectable tumours (inflammatory mammary carcinoma), or incomplete resection of tumours and as palliative treatment (Novosad, 2003). The major disadvantage of radiotherapy is the development of secondary tumours and other abnormalities such as fat necrosis (Looper, 2007). Moreover, radiation has been used to induce mammary cancers experimentally in dogs (Benjamin et al., 1999; Deeg et al., 1983). In an experimental study, intraoperative radiation therapy

was done on adult dogs to determine its short and long term effects on tissues and organs, leading to the development several types of cancers in the dogs (Barnes et al., 1990). This is also a similar scenario where radiotherapy has been associated with the development of lung cancer and cardiomyopathies in human patients diagnosed with breast cancer (Jabbari et al., 2013; Travis et al., 2012).

Prognostic Factors

Several prognostic factors have been identified for the dogs diagnosed with mammary tumours (Table 4). The prognostic factors may be associated with the dog itself, the tumour characteristics or even the various markers that the tumour expresses, where they have been described in reports as independent prognostic factors. Among the most important prognostic factors in CMT is the histopathological detection of regional lymph node metastasis (Klopfleisch et al., 2010a), that contributes to poor postsurgical survival (Rasotto et al., 2012).

Immunohistochemistry. Immunohistochemistry is a technique to specifically evaluate the distribution of protein or antigen in biological tissues using specific antibodies (Ramos-Vara, 2005). Immunohistochemistry is one of the popular techniques which is commonly used to describe and evaluate protein expression for prognosis, survival, predict response to therapy or even used to identify proteins/

antigens suitable for development of novel therapeutics. Markers that have been evaluated using immunohistochemistry on CMT are Ki67, Cox-2, proliferating cell nuclear antigen (PCNA), oestrogen receptor (ER) and progesterone receptor (PR), CD31, vascular endothelial growth factor (VEGF), vascular endothelial growth factor receptor-2 (VEGFR-2), E-cadherin and β -catenin (adhesion molecules),

human epidermal growth factor receptor (HER-2) (proto-oncogene), p53 (tumour suppressor), breast cancer susceptibility gene (BRCA1, BRCA2) (genetic stability gene) and p63 (myoepithelial cell nuclear marker). All the aforementioned markers are significant prognosticators (Cassali et al., 2011; Gama, Alves, Gartner, & Schmitt, 2003; Klopfleisch, Lenze, Hummel, & Gruber, 2010b; Queiroga et al., 2011).

Table 4
Prognostic indicators of canine mammary gland tumours

Factor	Influence on prognosis	References
Age	Shorter DFS and OS with increased age	(Bonnet, Egenvall, Hedhammar, & Olson, 2005; Hellmén et al., 1993; Schneider, Dorn, & Taylor, 1969; Simon, Schoenrock, Baumgärtner, & Nolte 2006)
Breed size	Small breed dogs have longer postsurgical survival	(Itoh et al., 2005)
Spay	Dogs spayed <2years before surgery survived longer than dogs spayed >2years before surgery	(Sorenmo et al., 2000)
Diet	Low fat high protein diet confers longer survival time than high fat low protein diet	(Sorenmo et al., 2000)
Clinical signs	Short duration of clinical signs have poor prognosis	(Sorenmo et al., 2000)
Clinical follow up	Lack of clinical follow up have poorer prognosis	(Matos et al., 2012)
Tumour size	>3cm have poor prognosis	(Matos et al., 2012; Sorenmo et al., 2000, 2011)
Tumour growth	Invasive growth confers poorer prognosis	(Matos et al., 2012; Sassi, Sarli, Brunetti, Morandi, & Benazzi, 2008)
Tumour grade	Grade 3 have poorer prognosis	(Hellmén et al., 1993; Sassi et al., 2008)
Tumour stage	High stage tumours have a shorter overall survival	(Hampe & Misdorp, 1974; Hellmén et al., 1993; Sorenmo et al., 2011)
Tumour type	Simple carcinoma has better prognosis, malignant mixed tumours, inflammatory carcinoma have poor prognosis, primary Sarcoma have poor prognosis,	(Benjamin et al., 1999; Sorenmo et al., 2011, 2000; Souza et al., 2009)
Lymph node	Metastasis to regional lymph node have poor prognosis	(Hellmén et al., 1993; Klopfleisch et al., 2010a; Sorenmo et al., 2011)
Metastasis	Distant metastasis has poor prognosis	(Sorenmo et al., 2000)
Hormones and receptors expression	Expression of oestrogen receptors and progesterone receptors confer better prognosis. Growth hormone and Insulin-like growth factor expression linked to poor prognosis	(Queiroga et al., 2005; Queiroga et al., 2011; Sleenckx et al., 2011; Sorenmo et al., 2011)
Proliferation markers	Ki67 and Proliferating cell nuclear antigen expression linked to poor prognosis	(Queiroga et al., 2005; Klopfleisch et al., 2011b; Zuccari et al., 2008)
Other markers expression	P53 mutation confers poor prognosis. EMT (Vimentin) expression confers poor prognosis. HER2 over expression confers poor prognosis. Interleukin 8 expression confers better prognosis. Cyclooxygenase 2 over expression confers poor prognosis	(Klopsfeisch et al., 2011; Queiroga et al., 2005; Rungsipipat et al., 1999; Sorenmo et al., 2011; Uva et al, 2009; Zuccari et al., 2011)

Carcinosarcomas showed high VEGFR-2 expression on immunohistochemistry which suggesting that it may be one of the activated molecular pathways in this aggressive tumour type and that VEGFR-2 inhibitors may be used as potential treatment to improve the prognosis of affected dogs. Both VEGF and VEGFR-2 immunoreactivities were independent of patients' overall survival (OS) and disease-free survival (DFS) (Santos, Lopes, Gärtner, & Matos, 2016). In a similar report, 26 canine simple mammary adenocarcinomas were found to express markers associated with angiogenesis including VEGF and VEGFR-2 at 96% and 100% of the tissues. Vascular endothelial growth factor may stimulate tumour cell proliferation through an autocrine loop, since VEGF and VEGFR-2 were expressed in most tumours (Al-Dissi, Haines, Singh, & Kidney, 2010). VEGF is able to increase the microvascular permeability (Nakamura, Savinov, Lu, & Brodie, 2013) thus, tumours with higher expression of VEGF and receptors may also stimulate the neoplastic cell migration through lymphatic vessels.

Ki-67. This antigen is a nuclear protein actively expressed in cycling cells, but not after mitosis (Gerdes et al., 1984). It has been found to be expressed in many tumours of the dog and man (Queiroga, Raposo, Carvalho, Prada, & Pires, 2011). A poor prognosis has been linked to immunohistochemical expression of Ki-67 in dogs with CMT (Peña, Nieto, Pérez-

Alenza, Cuesta, & Castaño, 1998). Ki-67 expression has been associated with a short disease free and overall survival time as well as correlates with advanced histologic tumour grade (Morris et al., 2009; Sarli, Preziosi, Benazzi, Castellani, & Marcato, 2002).

Proliferating Cell Nuclear Antigen

Knowing the proliferation status of any tumour is an important basis for the determination of the malignancy of the tumour and prognosis (Funakoshi et al., 2000; Torres et al., 2005). Proliferating cell nuclear antigen (PCNA) is a protein synthesised by cells in the S-phase of the cell cycle and it is seen accumulated in the nucleolus of the cells in the late G1 and early S-phases of the cell cycle (Mathews, Bernstein, Franza, & Garrels, 1984; van Dierendonck, Wijsman, Keijzer, van de Velde, & Cornelisse, 1991). Immunohistochemical detection of PCNA expressed in tumour cells has been critical in the evaluation of the proliferative activity of the tumours (Sarli et al., 2002). In CMT, PCNA expression has been found to correlate with aggression of tumours and has been described as an indicator of malignancy (Funakoshi et al., 2000; Peña et al., 1998; Queiroga et al., 2011; Torres et al., 2005).

In CMT, PCNA expression positively correlates with a shorter disease-free interval (Löhr, Teifke, Failing, & Weiss, 1997). Co-expression of PCNA and other prognostic markers have been analysed and PCNA expression is co-related with Ki-67 in dysplasias and benign mammary

tumours in the dog (Löhr et al., 1997; Nowak, Madej, Dziegiel, & Kanzawa, 2006; Peña et al., 1998). Expression of PCNA was found to inversely correlate with oestrogen receptor alpha (ER α) (Perez-Alenza et al., 2000). This finding suggests that as the tumour advances, hormonal dependency is lost and neoplastic cells increase in cell proliferation where malignancy is acquired.

Vimentin. Epithelial-mesenchymal transition (EMT) in tumours allows epithelial cells to transform into mesenchymal cells capable of migration and tissue invasion, which are the first steps in the establishment of metastasis (Wu et al., 2006). This transition is characterised by the overexpression of certain intermediate filaments such as Vimentin (Genelhu, Cardoso, Gobbi, & Cassali, 2007; Mendez, Kojima, & Goldman, 2010; Yoshida et al., 2013). Vimentin has been shown to be expressed in myoepithelial and mesenchymal cells, as well as overexpressed in CMT. Vimentin expression has also been used to identify CMT with luminal epithelial lineage (Griffey et al., 1993; Rabanal & Else, 1994; Toniti et al., 2009). However, the status of Vimentin as a prognosticator in CMT is yet to be ascertained as conflicting findings have been reported (Vos et al., 1993).

Oestrogen Receptor (ER). Oestrogen plays a major role in mammary gland development and oestrous cycle through the activation of oestrogen receptors (Chang et al., 2009; Martin De Las Mulas

et al., 2004; Rehm, Stanislaus, & Williams, 2007). Two forms of oestrogen receptors ER α and ER β have been reported in the literature (Chang et al., 2009). Favourable prognosis has been linked to oestrogen receptor expression in malignant mammary tumours (Martin De Las Mulas et al., 2004). Oestrogen receptors are reported to be expressed in more benign than malignant CMT (Chang et al., 2009). Tumours that are less than 5 cm in diameter and without nodal or distant metastasis are associated with oestrogen receptor expression (Chang et al., 2009).

Progesterone Receptor (PR).

Progesterone plays a significant role in oestrous cycle and pregnancy through the activation of progesterone receptors (Rehm et al., 2007). In canine mammary tumours, PR expressing tumours have been found to be more benign than malignant, less than 5cm in diameter have no lymph node or distant metastasis and the dogs survive longer than those with tumours expressing only Oestrogen receptors (Chang et al., 2009). Progesterone receptor has been targeted with success for therapy in PR positive canine mammary carcinoma cells (Guil-Luna et al., 2011). Absence of any correlation between PR expression and tumour subtype has also been reported in CMT (Toniti et al., 2009).

Recent Advancements in Therapeutics for CMT

There has been limited advancement in the improved or advanced therapies for dogs

with mammary tumour for the past decade. Several studies are underway investigating novel strategies, however most of the evidence is preliminary *in vitro* and *in vivo* mice models (Table 5). Increasing the awareness on spaying dogs at early age may collectively help reduce the incidence of CMT.

Table 5
Summary of new therapeutic approaches for canine mammary gland tumours on preliminary experimental investigations

Therapy/agent/ approach	Clinical subjects/ <i>in vivo</i> models	Mechanism/ research conclusion	References
Gold nanorods plasmonic photothermal therapy (AuNRs-PPTT)	5 female dogs (spontaneous clinical cases)	Causes heat-induced necrosis and apoptosis of the cancer cells leading to complete regression of tumours	(Ali, Ibrahim, Ali, Selim, & El-Sayed, 2016)
5-Azacytidine (5-AzaC)	Primary canine malignant adenocarcinoma cell lines	DNA methyl transferase (DNMT) inhibition in over expressing cancer cells	(Harman, Curtis, Argyle, Coonrod, & Van de Walle, 2016)
Reovirus (Oncolytic virus)	CMT cell lines and mice models	Reovirus causes caspase-dependent apoptosis in CMT cells and prevents development of tumours in mice. Enhances cytotoxic effects of chemotherapeutic drugs at half the IC50 in combination with reovirus	(Igase et al., 2016)
	CMT cell lines and mice models	Causes AMPK-independent cell cycle arrest <i>in vitro</i> and suppresses tumour development in mice models	(Saeki et al., 2015a)
Metformin	Mice models of lung metastatic CMT cell lines	Blocks EMT via N-cadherin, leading to reduction in metastases	(Leonel et al., 2017)
Mitochondrial respiratory chain complex inhibitors (antimycin, oligomycin and rotenone)	CMT cell lines (metastatic and non-metastatic clones)	Mitochondrial ATP depletion in cancer cells by the agents result in cell growth	(Saeki et al., 2015b)
Melphalan and BCH (2-amino-2-norbornane-carboxylic acids)	CMT cell lines	L-type amino acid transporter 1 (LAT1) inhibition	(Fukumoto et al., 2013)

Canine Mammary Gland Tumours, Animal Model for Human Breast Cancer

Mammary tumours are the most common naturally developed neoplasia in female dogs and women (Yoshikawa et al., 2012).

For the past decades, CMT has been suggested as a large animal spontaneous model for human breast cancer (Nerurkar, Chitale, Jalnapurkar, Naik, & Lalitha, 1989; Queiroga et al., 2011). This suggestion is supported by the epidemiological and

histopathological similarities that have been observed between the two (Queiroga et al., 2011) and the failure of mouse models (transgenic and xenografts) to mimic the tumour heterogeneity, dependence on steroids and tumour microenvironment, which are the essential features of human breast cancer (Uva et al., 2009).

The prevalence of mammary tumours is higher in dogs compared to women, which gives CMT an edge over human breast cancer in terms of availability for research and clinical trials (Queiroga et al., 2011; Nerurkar et al., 1989; Yoshikawa et al., 2012). Age as risk factor of mammary neoplasia has a somewhat similar influence in both human breast cancer and canine mammary gland tumours. It is reported that the age for onset of mammary tumours in dogs is after six years and peak age of occurrence is eight to 11 years, while 40 years of age is the reported onset age in human breast cancer and 50 to 58 years is the peak age of occurrence (Queiroga et al., 2011). The use of postmenopausal hormone replacement therapies have been linked to an increased risk of breast cancer in women (Amadou, Fabre, Torres-Mejía, & Ortega-Olvera, 2013) while the influence of ovarian hormones in CMT occurrence as demonstrated by early ovariectomy or lack of it has also been reported (Queiroga et al., 2011; Sorenmo et al., 2011). It has been reported that certain breeds are at a higher risk of developing CMT (Itoh et al., 2005), so in human breast cancer too, some races are reported to be more at risk compared to others (Pillai, Tay, Nair, & Leong,

2012; Sullivan et al., 2013). Other factors such as diet and obesity as risk factors for developing mammary tumours are also reported to have similar associations in both dogs and humans (Sonnenschein et al., 1991; Amadou et al., 2013).

The clinical presentation of mammary tumours is similar in dogs and humans, with patients presenting symptoms such as palpable masses of various sizes in the breast tissue or mammary gland chain, skin ulcerations, chest wall infiltration, enlarged lymph nodes, nipple retraction more notable in human, pain, and in some cases, pus or haemorrhage (Chang, Liao, Wong, Lai, & Liu, 2007; Grandi, Colodel, Rocha, & Sequeira, 2011; Nandeesh, Anitha, & Shravan Rajpurohit, 2013; Yoneyama & Nakamura, 2013). Large percentage of the tumours are diagnosed malignant and the most common site of metastasis is the regional lymph nodes, which significantly influence prognosis (Queiroga et al., 2011).

The methods of treatment in dogs with mammary gland tumours are very similar to the approach used in human breast cancer. Depending on the severity and stage of the disease, surgical approach is considered the most effective treatment, either alone or in combination with chemotherapy or hormonal therapy (Cassali et al., 2011; Yoneyama & Nakamura, 2013). Hormonal therapy is not commonly employed in CMT treatment due to toxicity of tamoxifen in dogs (Tavares et al., 2010). Chemotherapeutic agents commonly used in both species include Doxorubicin,

cyclophosphamide, piroxicam, and firocoxib, to mention a few (Cassali et al., 2011; Nandeesh et al., 2013; Novosad, 2003). Triple negative breast cancer (ER, PR- and HER2-) is the most difficult cancer phenotype to treat, due to its lack of steroid hormone dependency that could be targeted with Tamoxifen (Kabos, et al. 2012), and has also been described in the canine species, with similar characteristics (Kim, Lim, Im, Kim, & Sur, 2013). Factors affecting postsurgical survival in patients with breast cancer are similar with those predicting survival in dogs with mammary gland tumours (Philibert et al., 2003). Factors such as histologic tumour grade, tumour stage, presence of lymph node or distant metastasis, skin ulceration, increased age at diagnosis, oestrogen receptor, HER2, and BRCA expressions described to influence post-mastectomy survival in breast cancer patients have also been shown to influence postsurgical survival in dogs with mammary gland tumours (Perez-Alenza et al., 2000; Philibert et al., 2003; Chang et al., 2007). Histopathological findings and lesions of CMTs and human breast cancers have been demonstrated to be very similar, with very few histological subtypes described in human breast cancer and yet to be described in CMT (Goldschmidt et al., 2011). Staging and histopathology grading systems used in human breast cancers have been effectively applied in CMT with minimal or no modifications (Goldschmidt et al., 2011; Philibert et al., 2003). Several breast cancer susceptibility genes such as BRCA, HER2 and molecular markers are described as

risk and prognostic factors in human breast cancer. These genes and markers have been found with similar alterations, expression patterns and prognostic values in CMT (Klopfleisch, Schütze, & Gruber, 2010c; Queiroga et al., 2011; Rivera & Von Euler, 2011; Uva et al., 2009).

Current and future areas of research in both canine and human mammary gland tumours are all geared towards the discovery of novel molecular markers and therapeutic targets that will facilitate diagnosis, predict prognosis and possibly therapeutic targets (Queiroga et al., 2011).

CONCLUSION

Spontaneous canine mammary gland tumours have a significant and unique role in understanding cancer biology as well as in the development of new therapeutic agents for the effective treatment of the disease in humans and in dogs.

REFERENCES

- Al-Dissi, A. N., Haines, D. M., Singh, B., Kidney, B. A. (2010). Immunohistochemical expression of vascular endothelial growth factor and vascular endothelial growth factor receptor-2 in canine simple mammary gland adenocarcinomas. *Canadian Veterinary Journal*, 51(10), 1109-1114.
- Ali, M. R. K., Ibrahim, I. M., Ali, H. R., Selim, S. A., & El-Sayed, M. A. (2016). Treatment of natural mammary gland tumors in canines and felines using gold nanorods-assisted plasmonic photothermal therapy to induce tumor apoptosis. *International Journal of Nanomedicine*, 11, 4849-4863.

- Amadou, A., Fabre, A., Torres-Mejía, G., & Ortega-Olvera, C. (2013). Hormonal therapy and risk of breast cancer in Mexican women. *PLoS One*, 8(11), e79695.
- Andrade, F. H., Figueiroa, F. C., Bersano, P. R., Bissacot, D. Z., & Rocha, N. S. (2010). Malignant mammary tumor in female dogs: environmental contaminants. *Diagnostic Pathology*, 5(1), 45.
- Balfé, P., McCann, A., McGoldrick, A., McAllister, K., Kennedy, M., Dervan, P., & Kerin, M. J. (2004). Estrogen receptor alpha and beta profiling in human breast cancer. *European Journal of Surgical Oncology the Journal of the European Society of Surgical Oncology and the British Association of Surgical Oncology*, 30(5), 469-474.
- Barnes, M., Duray, P., DeLuca, A., Anderson, W., Sindelar, W., & Kinsella, T. (1990). Tumor induction following intraoperative radiotherapy: late results of the National Cancer Institute canine trials. *International Journal of Radiation Oncology, Biology, Physics*, 19(3), 651-660.
- Bastianello, S. S. (1983). A survey on neoplasia in domestic species over a 40-year period from 1935 to 1974 in the Republic of South Africa. VI. Tumours occurring in dogs. *The Onderstepoort Journal of Veterinary Research*, 50(3), 199-220.
- Benjamin, S. A., Lee, A. C., & Saunders, W. J. (1999). Classification and behavior of canine mammary epithelial neoplasms based on life-span observations in beagles. *Veterinary Pathology*, 36(5), 423-436.
- Bergman, P. J. (2012). Paraneoplastic hypercalcemia. *Topics in Companion Animal Medicine*, 27(4), 156-158.
- Bonnett, B. N., Egenvall, A., Hedhammar, Å., & Olson, P. (2005). Mortality in over 350,000 insured Swedish dogs from 1995–2000: Breed-, gender-, age- and cause-specific rates. *Acta Veterinaria Scandinavica*, 46(3), 105-120.
- Cassali, G. D., Lavalle, G. E., De Nardi, A. B., Ferreira, E., Bertagnolli, A. C., Estrela-Lima, A., ... & Sobral, R. A. (2011). Consensus for the diagnosis, prognosis and treatment of canine mammary tumors. *Brazilian Journal of Veterinary Pathology*, 4(2), 153-180.
- Chang, C. C., Tsai, M. H., Liao, J. W., Chan, J. P. W., Wong, M. L., & Chang, S. C. (2009). Evaluation of hormone receptor expression for use in predicting survival of female dogs with malignant mammary gland tumors. *Journal of the American Veterinary Medical Association*, 235(4), 391-396.
- Chang, S. C., Liao, J. W., Wong, M. L., Lai, Y. S., & Liu, C. I. (2007). Mammary carcinoma with sebaceous differentiation in a dog. *Veterinary Pathology*, 44(4), 525-527.
- Clemente, M., Sánchez-Archidona, A. R., Sardón, D., Diez, L., Martín-Ruiz, A., Caceres, S., et al. (2013). Different role of COX-2 and angiogenesis in canine inflammatory and non-inflammatory mammary cancer. *The Veterinary Journal*, 197(2), 427-432.
- Crivellenti, L. Z., Silva, G. E., Borin-Crivellenti, S., Cianciolo, R., Adin, C. A., Dantas, M., ... & Santana, A. E. (2016). Prevalence of glomerulopathies in canine mammary carcinoma. *PLoS ONE*, 11(10), 1-10.
- Deeg, H. J., Prentice, R., Fritz, T. E., Sale, G. E., Lombard, L. S., Thomas, E. D., & Storb, R. (1983). Increased incidence of malignant tumors in dogs after total body irradiation and marrow transplantation. *International Journal of Radiation Oncology, Biology, Physics*, 9(10), 1505-1511.
- DeMauro, S., & Wysolmerski, J. (2005). Hypercalcemia in breast cancer: An echo of bone mobilization during lactation? *Journal of Mammary Gland Biology and Neoplasia*, 10(2), 157-167.

- Dhami, M. A., Tank, P. H., Karle, A. S., Vedpathak, H. S., & Bhatia, A. S. (2010). Epidemiology of canine mammary gland tumours in Gujarat, veterinary world, 3(6), 282-285.
- Dobson, J. M., Samuel, S., Milstein, H., Rogers, K., & Wood, J. L. N. (2002). Canine neoplasia in the UK: Estimates of incidence rates from a population of insured dogs. *The Journal of Small Animal Practice*, 43(6), 240-246.
- Egenvall, A., Bonnett, B. N., Ohagen, P., Olson, P., Hedhammar, A., & Von Euler, H. (2005). Incidence of and survival after mammary tumors in a population of over 80,000 insured female dogs in Sweden from 1995 to 2002. *Preventive Veterinary Medicine*, 69(1-2), 109-127.
- Ferreira, E., Bertagnolli, A. C., Cavalcanti, M. F., Schmitt, F. C., & Cassali, G. D. (2009). The relationship between tumour size and expression of prognostic markers in benign and malignant canine mammary tumours. *Veterinary and Comparative Oncology*, 7(4), 230-235.
- Fukumoto, S., Hanazono, K., Komatsu, T., Ueno, H., Kadosawa, T., Iwano, H., & Uchide, T. (2013). L-type amino acid transporter 1 (LAT1): A new therapeutic target for canine mammary gland tumour. *The Veterinary Journal*, 198(1), 164-169.
- Funakoshi, Y., Nakayama, H., Uetsuka, K., Nishimura, R., Sasaki, N., & Doi, K. (2000). Cellular proliferative and telomerase activity in canine mammary gland tumors. *Veterinary Pathology*, 37(2), 177-183.
- Gama, A., Alves, A., Gartner, F., & Schmitt, F. (2003). P63: A novel myoepithelial cell marker in canine mammary tissues. *Veterinary Pathology*, 40(4), 412-420.
- Genelhu, M. C. L. S., Cardoso, S. V, Gobbi, H., & Cassali, G. D. (2007). A comparative study between mixed-type tumours from human salivary and canine mammary glands. *BMC Cancer*, 7(1), 218.
- Gerdes, J., Lemke, H., Baisch, H., Wacker, H. H., Schwab, U., & Stein, H. (1984). Cell cycle analysis of a cell proliferation-associated human nuclear antigen defined by the monoclonal antibody Ki-67. *Journal of Immunology*, 133(4), 1710-1715.
- Goldschmidt, M., Peña, L., Rasotto, R., & Zappulli, V. (2011). Classification and grading of canine mammary tumors. *Veterinary Pathology*, 48(1), 117-131.
- Gräf, K., & Etreby, M. E. (1978). Endocrinology of reproduction in the female beagle dog and its significance in mammary gland tumorigenesis. *Acta Endocrinologica. Supplementum*, 222, 1-34.
- Grandi, F., Colodel, M. M., Rocha, R. M., & Sequeira, J. L. (2011). Sebaceous metaplasia in a canine mammary gland non-infiltrative carcinoma with myoepithelial component. *Journal of Veterinary Diagnostic Investigation*, 23(6), 1230-1233.
- Griffey, S. M., Madewell, B. R., Dairkee, S. H., Hunt, J. E., Naydan, D. K., & Higgins, R. J. (1993). Immunohistochemical reactivity of basal and luminal epithelium-specific cytokeratin antibodies within normal and neoplastic canine mammary glands. *Veterinary Pathology*, 30(2), 155-161.
- Guil-Luna, S., Sánchez-Céspedes, R., Millan, Y., De Andres, F. J., Rollon, E., Domingo, V., ... & Martín de Las Mulas, J. (2011). Aglepristone decreases proliferation in progesterone receptor-positive canine mammary carcinomas. *Journal of Veterinary Internal Medicine / American College of Veterinary Internal Medicine*, 25(3), 518-523.
- Hampe, J. F., & Misdorp, W. (1974). Tumours and dysplasias of the mammary gland. *Bulletin of the World Health Organization*, 50(1-2), 111-133.

- Harman, R. M., Curtis, T. M., Argyle, D. J., Coonrod, S. A., & Van de Walle, G. R. (2016). A comparative study on the in vitro effects of the DNA methyltransferase inhibitor 5-azacytidine (5-AzaC) in breast/mammary cancer of different mammalian species. *Journal of Mammary Gland Biology and Neoplasia*, 21(1-2), 51-66.
- Hellmén, E., Bergström, R., Holmberg, L., Spångberg, I. B., Hansson, K., & Lindgren, A. (1993). Prognostic factors in canine mammary tumors: A multivariate study of 202 consecutive cases. *Veterinary Pathology*, 30(1), 20-27.
- Hellmén, E., & Lindgren, A. (1989). The accuracy of cytology in diagnosis and DNA analysis of canine mammary tumours. *Journal of Comparative Pathology*, 101(4), 443-450.
- Igase, M., Hwang, C. C., Kambayashi, S., Kubo, M., Coffey, M., Miyama, T. S., ... & Mizuno, T. (2016). Oncolytic reovirus synergizes with chemotherapeutic agents to promote cell death in canine mammary gland tumor. *Canadian Journal of Veterinary Research = Revue Canadienne de Recherche Veterinaire*, 80(1), 21-31.
- Itoh, T., Uchida, K., Ishikawa, K., Kushima, K., Kushima, E., Tamada, H., ... & Shii, H. (2005). Clinicopathological survey of 101 canine mammary gland tumors: differences between small-breed dogs and others. *The Journal of Veterinary Medical Science the Japanese Society of Veterinary Science*, 67(3), 345-347.
- Jabbari, K., Azarmahd, N., Babazade, S., & Amouheidari, A. (2013). Optimizing of the tangential technique and supraclavicular fields in 3 dimensional conformal radiation therapy for breast cancer. *Journal of Medical Signals and Sensors*, 3(2), 107-116.
- Kabos, P., Finlay-Schultz, J., Li, C., Kline, E., Finlayson, C., Wisell, J., ... & Sartorius, C. A. (2012). Patient-derived luminal breast cancer xenografts retain hormone receptor heterogeneity and help define unique estrogen-dependent gene signatures. *Breast Cancer Research and Treatment*, 135(2), 415-432.
- Karayannopoulou, M., Kaldrymidou, E., Constantinidis, T. C., & Dessiris, A. (2005). Histological grading and prognosis in dogs with mammary carcinomas: application of a human grading method. *Journal of Comparative Pathology*, 133(4), 246-52.
- Kelsey, J. L., Moore, A. S., & Glickman, L. T. (1998). Epidemiologic studies of risk factors for cancer in pet dogs. *Epidemiologic Reviews*, 20(2), 204-217.
- Kim, J. H., Im, K. S., Kim, N. H., Chon, S. K., Doster, A. R., & Sur, J. H. (2011). Inflammatory mammary carcinoma with metastasis to the brain and distant organs in a spayed Shih Tzu dog. *Journal of Veterinary Diagnostic Investigation*, 23(5), 1079-1082.
- Kim, N. H., Lim, H. Y., Im, K. S., Kim, J. H., & Sur, J. H. (2013). Identification of triple-negative and basal-like canine mammary carcinomas using four basal markers. *Journal of Comparative Pathology*, 148(4), 298-306.
- Klopfleisch, R., Lenze, D., Hummel, M., & Gruber, A. D. (2011a). The metastatic cascade is reflected in the transcriptome of metastatic canine mammary carcinomas. *Veterinary Journal*, 190(2), 236-243.
- Klopfleisch, R., Klose, P., Weise, C., Bondzio, A., Multhaup, G., Einspanier, R., & Gruber, A. D. (2010a). Proteome of metastatic canine mammary carcinomas: similarities to and differences from human breast cancer. *Journal of Proteome Research*, 9(12), 6380-6391.

- Klopfleisch, R., Lenze, D., Hummel, M., & Gruber, A. D. (2010b). Metastatic canine mammary carcinomas can be identified by a gene expression profile that partly overlaps with human breast cancer profiles. *BMC Cancer*, *10*(1), 618.
- Klopfleisch, R., Lenze, D., Hummel, M., & Gruber, A. D. (2011b). The metastatic cascade is reflected in the transcriptome of metastatic canine mammary carcinomas. *Veterinary Journal*, *190*(2), 236-243.
- Klopfleisch, R., Schütze, M., & Gruber, A. D. (2010c). Loss of p27 expression in canine mammary tumors and their metastases. *Research in Veterinary Science*, *88*(2), 300-303.
- Klopfleisch, R., von Euler, H., Sarli, G., Pinho, S. S., Gärtner, F., & Gruber, A. D. (2011c). Molecular carcinogenesis of canine mammary tumors: news from an old disease. *Veterinary Pathology*, *48*(1), 98-116.
- Lallo, M. A., Ferrarias, T. M., Stravino, A., Rodriguez, J. F. M., & Zucare, R. L. C. (2016). Alterações hematológicas em cadelas portadoras de tumores de mama [Hematologic abnormalities in dogs bearing mammary tumors]. *Revista Brasileira de Ciência Veterinária*, *23*(1/2), 3-8.
- Leonel, C., Borin, T. F., de Carvalho Ferreira, L., Moschetta, M. G., Bajgelman, M. C., Viloria-Petit, A. M., & de Campos Zuccari, D. A. P. (2017). Inhibition of epithelial-mesenchymal transition and metastasis by combined TGFbeta knockdown and metformin treatment in a canine mammary cancer Xenograft Model. *Journal of Mammary Gland Biology and Neoplasia*, *22*(1), 27-41.
- Löhr, C. V., Teifke, J. P., Failing, K., & Weiss, E. (1997). Characterization of the proliferation state in canine mammary tumors by the standardized AgNOR method with postfixation and immunohistologic detection of Ki-67 and PCNA. *Veterinary Pathology*, *34*(3), 212-221.
- Looper, J. S. (2007). Fat necrosis simulating recurrent neoplasia following external beam radiotherapy in a dog. *Veterinary Radiology and Ultrasound*, *48*(1), 86-88.
- MacEwen, E. G., Patnaik, A. K., Harvey, H. J., & Panko, W. B. (1982). Estrogen receptors in canine mammary tumors. *Cancer Research*, *42*(6), 2225-2229.
- Martín De Las Mulas, J., Ordás, J., Millán, M. Y., Chacón, F., De Lara, M., Espinosa De Los Monteros, A., ... & Jover, A. (2004). Immunohistochemical expression of estrogen receptor beta in normal and tumoral canine mammary glands. *Veterinary Pathology*, *41*(3), 269-272.
- Mathews, M. B., Bernstein, R. M., Franza, B. R., & Garrels, J. I. (1984). Identity of the proliferating cell nuclear antigen and cyclin. *Nature*, *309*(5966), 374-376.
- Matos, A. J. F., Baptista, C. S., Gärtner, M. F., & Rutteman, G. R. (2012). Prognostic studies of canine and feline mammary tumours : The need for standardized procedures. *The Veterinary Journal*, *193*(1), 24-31.
- Mendez, M. G., Kojima, S.-I., & Goldman, R. D. (2010). Vimentin induces changes in cell shape, motility, and adhesion during the epithelial to mesenchymal transition. *The FASEB Journal*, *24*(6), 1838-1851.
- Merlo, D. F., Rossi, L., Pellegrino, C., Ceppi, M., Cardellino, U., Capurro, C., ... & Bocchini, V. (2008). Cancer incidence in pet dogs: Findings of the Animal Tumor Registry of Genoa, Italy. *Journal of Veterinary Internal Medicine / American College of Veterinary Internal Medicine*, *22*(4), 976-84.
- Misdorp, W., Else, R. W., & Hellmen, E. L. T. (1999). *Histologic classification of mammary tumours of the dog and the cat* (2nd ser., vol. 7.). Washington, D.C.: Armed Force Institute of Pathology and World Health Organization.

- Mitchell, L., De la Iglesia, F. A., Wenkoff, M. S., Van Dreumel, A. A., & Lumb, G. (1974). Mammary tumors in dogs: survey of clinical and pathological characteristics. *The Canadian Veterinary Journal. La Revue Vétérinaire Canadienne*, 15(5), 131-138.
- Morris, J. S., Nixon, C., King, O. J. A., Morgan, I. M., & Philbey, A. W. (2009). Expression of TopBP1 in canine mammary neoplasia in relation to histological type, Ki67, ERalpha and p53. *Veterinary Journal*, 179(3), 422-429.
- Nakamura, J., Saviniov, A., Lu, Q., Brodie, A. (2013). Estrogen regulates vascular endothelial growth/permeability factor expression in 7,12dimethylbenz(a)anthracene-induced rat mammary tumors. *Endocrinology*, 137(12), 5589-5596.
- Nandeesh, M., Anitha, T. K., & Shravan Rajpurohit, S. R. (2013). Neuroendocrine Carcinoma of Breast: A Rare Case Vignette. *Journal of clinical and diagnostic research: JCDR*, 7(11), 2585.
- Nerurkar, V. R., Chitale, A. R., Jalnapurkar, B. V., Naik, S. N., & Lalitha, V. S. (1989). Comparative pathology of canine mammary tumours. *Journal of Comparative Pathology*, 101(4), 389-397.
- Novosad, C. A. (2003). Principles of treatment for mammary gland tumors. *Clinical Techniques in Small Animal Practice*, 18(2), 107-109.
- Nowak, M., Madej, J. A., Dziegiel, P., & Kanzawa, H. (2006). Immunohistochemical identification method of tumour cells in the S phase of mitotic cycle and its usefulness in diagnostics of mammary gland adenocarcinomas in bitches. *Polish Journal of Veterinary Sciences*, 9(1), 57-62.
- Owens L. N. (1980). *Classification of tumors in domestic animals* (1st Ed.). Geneva: World Health Organization.
- Peña, L. L., Nieto, A. I., Pérez-Alenza, D., Cuesta, P., & Castaño, M. (1998). Immunohistochemical detection of Ki-67 and PCNA in canine mammary tumors: Relationship to clinical and pathologic variables. *Journal of Veterinary Diagnostic Investigation*, 10(3), 237-246.
- Perez-Alenza, M. D., Peña, L., Del Castillo, N., & Nieto, A. I. (2000). Incidence and prognosis of canine mammary tumours. *The Journal of Small Animal Practice*, 41(10), 476-476.
- Philibert, J. C., Snyder, P. W., Glickman, N., Glickman, L. T., Knapp, D. W., & Waters, D. J. (2003). Influence of host factors on survival in dogs with malignant mammary gland tumors. *Journal of Veterinary Internal Medicine American College of Veterinary Internal Medicine*, 17(1), 102-106.
- Pllai, S. K., Tay, A., Nair, S., & Leong, C. O. (2012). Triple-negative breast cancer is associated with EGFR, CK5/6 and c-KIT expression in Malaysian women. *BMC Clinical Pathology*, 12(1), 18.
- Queiroga, F. L., Pérez-Alenza, M. D., Silvan, G., Peña, L., Lopes, C., & Illera, J. C. (2005). Role of steroid hormones and prolactin in canine mammary cancer. *The Journal of Steroid Biochemistry and Molecular Biology*, 94(1-3), 181-187.
- Queiroga, F. L., Raposo, T., Carvalho, M. I., Prada, J., & Pires, I. (2011). Canine mammary tumours as a model to study human breast cancer: most recent findings. *In Vivo (Athens, Greece)*, 25(3), 455-465.
- Rabanal, R. M., & Else, R. W. (1994). Immunohistochemical localisation of cytokeratin and vimentin intermediate filament proteins in canine mammary tumours. *Research in Veterinary Science*, 56(2), 225-233.
- Ramos-Vara, J. A. (2005). Technical aspects of immunohistochemistry. *Veterinary Pathology*, 42(4), 405-26.

- Rasotto, R., Zappulli, V., Castagnaro, M., & Goldschmidt, M. H. (2012). A retrospective study of those histopathologic parameters predictive of invasion of the lymphatic system by canine mammary carcinomas. *Veterinary Pathology*, 49(2), 330-340.
- Rehm, S., Stanislaus, A. D. J., & Williams, A. M. (2007). Estrous cycle-dependent histology and review of sex steroid receptor expression in dog reproductive tissues and mammary gland and associated hormone levels, 245(Issue), 233-245.
- Rivera, P., & Von Euler, H. (2011). Molecular biological aspects on canine and human mammary tumors. *Veterinary Pathology*, 48(1), 132-146.
- Rungsipipat, A., Tateyama, S., Yamaguchi, R., Uchida, K., Miyoshi, N., & Hayashi, T. (1999). Immunohistochemical analysis of c-yes and c-erbB-2 oncogene products and p53 tumor suppressor protein in canine mammary tumors. *The Journal of Veterinary Medical Science / the Japanese Society of Veterinary Science*, 61(1), 27-32.
- Rutteman G. R., & Withrow S. J. (2001). Tumors of the mammary gland. In E. M. S. J. Withrow (Ed.), *Small animal clinical oncology* (3rd ed.) (pp. 455–477). Philadelphia, PA: WB Saunders.
- Saeki, K., Watanabe, M., Michishita, M., Tsuboi, M., Sugano, S., Yoshitake, R., ... & Matsumoto, K. (2015a). Phenotypic screening of a library of compounds against metastatic and non-metastatic clones of a canine mammary gland tumour cell line. *The Veterinary Journal*, 205(2), 288-296.
- Saeki, K., Watanabe, M., Tsuboi, M., Sugano, S., Yoshitake, R., Tanaka, Y., ... & Nishimura, R. (2015b). Anti-tumour effect of metformin in canine mammary gland tumour cells. *The Veterinary Journal*, 205(2), 297-304.
- Sahabi, K., Selvarajah, G. T., & Noordin M. M., Sharma, R. S. K., & Dhaliwal, G. K. (2015). Retrospective Histopathological Study of Canine Mammary Gland Tumours Diagnosed from 2006 – 2012 in Universiti Putra Malaysia. *Journal of Veterinary Malaysia*, 27(1), 1–6.
- Santos, A. A., Lopes, C. C., Ribeiro, J. R., Martins, L. R., Santos, J. C., Amorim, I. F., ... & Matos, A. J. (2013). Identification of prognostic factors in canine mammary malignant tumours: A multivariable survival study. *BMC Veterinary Research*, 9(1), 1.
- Santos, A., Lopes, C., Gärtner, F., Matos, A. J. (2016). VEGFR-2 expression in malignant tumours of the canine mammary gland: A prospective survival study. *Veterinary and comparative oncology*, 4(3), 83-92.
- Santos, M., Marcos, R., & Faustino, A. M. R. (2010). Histological Study of Canine Mammary Gland During the Oestrous Cycle. *Reproduction in Domestic Animals*, 45(5), 146-154.
- Sarli, G., Preziosi, R., Benazzi, C., Castellani, G., & Marcato, P. S. (2002). Prognostic value of histologic stage and proliferative activity in canine malignant mammary tumors. *Journal of Veterinary Diagnostic Investigation*, 14(1), 25-34.
- Sassi, F., Sarli, G., Brunetti, B., Morandi, F., & Benazzi, C. (2008). Immunohistochemical characterization of mammary squamous cell carcinoma of the dog. *Journal of Veterinary Diagnostic Investigation*, 20(6), 766-773.
- Schneider, R., Dorn, C. R., & Taylor, D. O. (1969). Factors influencing canine mammary cancer development and postsurgical survival. *Journal of the National Cancer Institute*, 43(6), 1249-1261.

- Simon, D., Schoenrock, D., Baumgärtner, W., & Nolte, I. (2006). Postoperative adjuvant treatment of invasive malignant mammary gland tumors in dogs with doxorubicin and docetaxel. *Journal of Veterinary Internal Medicine / American College of Veterinary Internal Medicine*, 20, 1184-1190.
- Sleeckx, N., de Rooster, H., Veldhuis Kroeze, E. J. B., Van Ginneken, C., & Van Brantegem, L. (2011). Canine mammary tumours, an overview. *Reproduction in Domestic Animals = Zuchthygiene*, 46(6), 1112-31.
- Sonnenschein, E. G., Glickman, L. T., Goldschmidt, M. H., & McKee, L. J. (1991). Body conformation, diet, and risk of breast cancer in pet dogs: A case-control study. *American Journal of Epidemiology*, 133(7), 694-703.
- Sorenmo, K. (2003). Canine mammary gland tumors. *The Veterinary Clinics of North America. Small Animal Practice*, 33(3), 573-576.
- Sorenmo, K. U., Rasotto, R., Zappulli, V., & Goldschmidt, M. H. (2011). Development, anatomy, histology, lymphatic drainage, clinical features, and cell differentiation markers of canine mammary gland neoplasms. *Veterinary Pathology*, 48(1), 85-97.
- Sorenmo, K. U., Shofer, F. S., & Goldschmidt, M. H. (2000). Effect of spaying and timing of spaying on survival of dogs with mammary carcinoma. *Journal of Veterinary Internal Medicine American College of Veterinary Internal Medicine*, 14(3), 266-270.
- Souza, C. H. D. M., Toledo-piza, E., Amarin, R., Barboza, A., & Tobias, K. M. (2009). Inflammatory mammary carcinoma in 12 dogs: Clinical features, cyclooxygenase-2 expression, and response to piroxicam treatment, *The Canadian Veterinary Journal*, 50(5), 506.
- Srivastava, A. K., Sharma, A. K., & Singh, B. (2009). Canine mammary tumours : A study on occurrence and distribution pattern, 33(1), 109-111.
- Sullivan, H. C., Oprea-Ilies, G., Adams, A. L., Page, A. J., Kim, S., Wang, J., et al. (2013). Triple-negative breast carcinoma in African American and Caucasian women: Clinicopathology, immunomarkers, and outcome. *Applied Immunohistochemistry and Molecular Morphology*, 22(1), 17-23.
- Tavares, W. L., Lavalle, G. E., Figueiredo, M. S., Souza, A. G., Bertagnolli, A. C., Viana, F. A., ... & Cassali, G. D. (2010). Evaluation of adverse effects in tamoxifen exposed healthy female dogs. *Acta Veterinaria Scandinavica*, 52(1), 67.
- Taylor, G. N., Shabestari, L., Williams, J., Mays, C. W., Angus, W., & McFarland, S. (1976). Mammary neoplasia in a closed beagle colony. *Cancer Research*, 36(8), 2740-2743.
- Toniti, W., Buranasinsup, S., Kongcharoen, A., Puchadapirom, P., & Kasorndorkbua, C. (2009). Immunohistochemical determination of estrogen and progesterone receptors in canine mammary tumors, *Name of Journal*, 10, 907-912.
- Torres, L. N., Matera, J. M., Vasconcellos, C. H., Avanzo, J. L., Hernandez-Blazquez, F. J., & Dagli, M. L. Z. (2005). Expression of connexins 26 and 43 in canine hyperplastic and neoplastic mammary glands. *Veterinary Pathology*, 42(5), 633-641.
- Travis, L. B., Ng, A. K., Allan, J. M., Pui, C.-H., Kennedy, A. R., & Xu, X. G. (2012). Second malignant neoplasms and cardiovascular disease following radiotherapy. *Journal of the National Cancer Institute*, 104(5), 357-370.
- Uva, P., Aurisicchio, L., Watters, J., Loboda, A., Kulkarni, A., Castle, J., ... & Marconato, L. (2009). Comparative expression pathway analysis of human and canine mammary tumors. *BMC Genomics*, 10(1), 135.
- Valenčáková-Agyagosová, A., & Ledecký, V. (2011). Incidence of Mammary Gland Tumors in Bitches admitted to the University of Veterinary Medicine And Pharmacy In Košice In. *Folia*, 55(4), 162-166.

- van Dierendonck, J. H., Wijsman, J. H., Keijzer, R., van de Velde, C. J., & Cornelisse, C. J. (1991). Cell-cycle-related staining patterns of anti-proliferating cell nuclear antigen monoclonal antibodies. Comparison with BrdUrd labeling and Ki-67 staining. *The American Journal of Pathology*, 138(5), 1165-72.
- Vos, J. H., Van den Ingh, T. S. G. A. M., Misdorp, W., Molenbeek, R. F., Van Mil, F. N., Rutteman, G. R., ... & Ramaekers, F. C. S. (1993). Immunohistochemistry with keratin, vimentin, desmin, and alpha-smooth muscle actin monoclonal antibodies in canine mammary gland: malignant mammary tumours. *The Veterinary Quarterly*, 15(3), 96-102.
- Woodhouse, E. C., Chuaqui, R. F., & Liotta, L. A. (1997). General mechanisms of metastasis. *Cancer*, 80(8 Suppl), 1529-1537.
- Wu, X., Chen, H., Parker, B., Rubin, E., Zhu, T., Lee, J. S., ... & Sukumar, S. (2006). HOXB7, a homeodomain protein, is overexpressed in breast cancer and confers epithelial-mesenchymal transition. *Cancer Research*, 66(19), 9527-9534.
- Yamagami, T., Kobayashi, T., Takahashi, K., & Sugiyama, M. (1996). Prognosis for canine malignant mammary tumors based on TNM and histologic classification. *The Journal of Veterinary Medical Science / the Japanese Society of Veterinary Science*, 58(11), 1079-1083.
- Yoneyama, K., & Nakamura, H. (2013). An elderly patient with advanced breast cancer who responded to treatment with letrozole—a case report. *Gan to Kagaku Ryoho. Cancer & Chemotherapy*, 40(13), 2565-2567.
- Yoshida, K., Saito, T., Kamida, A., Matsumoto, K., Saeki, K., Mochizuki, M., ... & Nakagawa, T. (2013). Transforming growth factor- β transiently induces vimentin expression and invasive capacity in a canine mammary gland tumor cell line. *Research in Veterinary Science*, 94(3), 539-541.
- Yoshikawa, Y., Ochiai, K., Morimatsu, M., Suzuki, Y., Wada, S., Taoda, T., ... & Watanabe, K. (2012). Effects of the missense mutations in canine BRCA2 on BRC repeat 3 functions and comparative analyses between canine and human BRC repeat 3. *PloS One*, 7(10), e45833.
- Zatloukal, J., Lorenzova, J., & Tichý, F. (2005). Breed and age as risk factors for canine mammary tumours. *Acta Veterinaria Brno* 74(1), 103-109.
- Zuccari, D. A. P. C., Castro, R., Gelaleti, G. B., & Mancini, U. M. (2011). Interleukin-8 expression associated with canine mammary tumors. *Genetics and Molecular Research GMR*, 10(3), 1522-1532.
- Zuccari, D. A., Pavam, M. V., Terzian, C. B., Pereira, R. S., Ruiz, C. M., & Andrade, J. C. (2008). Immunohistochemical evaluation of e-cadherin, Ki-67 and PCNA in canine mammary neoplasias: correlation of prognostic factors and clinical outcome. *Pesquisa Veterinária Brasileira*, 28(4), 207-215.