

Microsporium canis and *Sporothrix schenckii*: Fungi Causing Skin Infections in Cats

Aina Nazurah Mohd-Khlubi¹, Sharina Omar^{1*}, Siti Khairani-Bejo² and Puteri Azaziah Megat Abd-Rani³

¹Department of Veterinary Pathology and Microbiology, Faculty of Veterinary Medicine, Universiti Putra Malaysia, 43400 Serdang, Selangor, Malaysia

²Department of Companion Animal Medicine and Surgery, Faculty of Veterinary Medicine, Universiti Putra Malaysia, 43400 Serdang, Selangor, Malaysia

³Abd-Rani, P. A. M., Jade Hills Veterinary Hospital Sdn. Bhd., 43000 Kajang, Selangor, Malaysia

ABSTRACT

Companion animals such as cats help to reduce stress among people as they delight their owners in their ways. Good management and hygiene practices of pets help in keeping them in a healthy condition. Nevertheless, since fungal infection develops rapidly, there is a high tendency for them to get infected. The paucity of data regarding skin mycoses among cats in Malaysia leads to this study. Private veterinary clinics from the Central Region of Peninsular Malaysia were approached for participation in this study. Sampling was conducted for one year, collecting hair plucked, skin scrapings, and swabs from lesions of the cats with skin problems and inoculating onto Sabouraud Dextrose Agar media. Diagnosing the fungal colony was conducted through a direct examination method using lactophenol cotton blue stain and molecular identification of the isolates using polymerase chain reaction targeting the fungi species' internal transcribed spacer region and β -tubulin gene. Of the 127 cats, 93 were positively infected, mainly with *Microsporium canis* (n = 38) and *Sporothrix schenckii* (n = 26). Saprophytic fungi detected on cats were *Alternaria* sp., *Aspergillus* sp., *Candida* sp., *Chaetomium* sp., *Chrysosporium* sp., *Curvularia* sp.,

Fusarium sp., *Geotrichum* sp., *Penicillium* sp., *Talaromyces* sp., *Trichoderma* sp., *Trichosporon* sp., and *Xylaria* sp. This finding represents the number of cats infected with fungal dermatitis in Selangor, Negeri Sembilan, the Federal Territory of Kuala Lumpur, and Putrajaya.

ARTICLE INFO

Article history:

Received: 08 June 2023

Accepted: 29 September 2023

Published: 22 July 2024

DOI: <https://doi.org/10.47836/pjtas.47.3.04>

E-mail addresses:

aina_nazurah232@yahoo.com (Aina Nazurah Mohd-Khlubi)

sharina@upm.edu.my (Sharina Omar)

skhairani@upm.edu.my (Siti Khairani-Bejo)

puteriazaziah@gmail.com (Puteri Azaziah Megat Abd-Rani)

*Corresponding author

Keywords: Cat, Central Region of Peninsular Malaysia, *Microsporium canis*, skin problems, *Sporothrix schenckii*

INTRODUCTION

Cats are among the favourable companion animals due to their characteristic that a human easily attracts. Despite bringing joy to humans, the health management of pets should be taken seriously, as some animal diseases are zoonotic and can be transmitted to humans. The development of fungal infections among companion animals has greatly increased globally after bacterial and viral infections, which are known to be the major factors that trigger animal diseases (Seyedmousavi et al., 2018).

Malaysia is a small country divided into six main regions: the Northern Region, the Central Region, the Southern Region, Sabah, and Sarawak. The Central Region is known to be the nation's hub. It comprises Selangor, Negeri Sembilan, the Federal Territories of Kuala Lumpur (the capital of Malaysia), and Putrajaya (the administrative and judicial capital) (Lim, 2002). A survey conducted in Putrajaya revealed that 47% of the households kept animals as their pets, with most respondents (72%) from Precincts 9 and 5 having cats (Debra et al., 2019).

In Malaysia, sporotrichosis was detected by the Faculty of Veterinary Medicine, Universiti Putra Malaysia (UPM) on five adult male crossbred cats that had ulcerated wounds mostly on their forelimbs, cheek, and nose because of fighting between them (Zamri-Saad et al., 1990). As sporotrichosis is zoonotic, four students who treated the infected cats were also infected with the same infection through the cats' bites and scratches (Zamri-Saad et al., 1990). The sporotrichosis among cats in Malaysia is reported to be caused by cats' fighting and

contact with a contaminated environment (Kano et al., 2015). From 1990 to 2010, only 12 cases of feline sporotrichosis were reported, and the number has increased recently; the University Veterinary Hospital at UPM recorded 80 cases in a year related to feline sporotrichosis in Selangor from 2008 to 2012 (Azam et al., 2019).

Nevertheless, aside from sporotrichosis, few fungal infections in cats were reported in Malaysia. Since Malaysia is a tropical climate country, the environment is suitable for fungal growth. Thus, this study aims to indicate fungal infection among pet cats in the Central Region of Peninsular Malaysia. Perhaps this study will help the community and animal handlers gain knowledge and exposure regarding skin mycoses in companion animals, specifically cats.

MATERIAL AND METHODS

Sample Collection

The participating veterinary clinics around the Central Region of Peninsular Malaysia were provided with owners' consent forms, research location consent forms and questionnaires about their cats' management. The veterinary clinics also provided sampling kits comprised of sterile petri dishes, sterile swabs with Amies transport media and sterile scalpel blades for specimen collecting purposes. The clinicians sampled only cats with skin lesions suspected of skin fungal diseases such as ulcerated wounds, erythema, papules, alopecia, scaling, and their hair and skin crusting. No asymptomatic cats were sampled in this study as it is deemed that the spores are ubiquitously present in

the environment and do not cause lesions in healthy animals. Samples (s) collected can be either hair plucked and/or skin scraping for suspected dermatophytosis cases and/or swabs taken from ulcerated wounds for suspected sporotrichosis cases of the cats from the infected area. The sampled cats consisted of both sexes, different types of breeds and age groups. The sampling was held for a year, from November 2018 to November 2019. The total cats sampled were 127 (n), comprised of hair plucked (s = 80) from 55 cats, skin scraping (s = 37) from 29 cats, a swab from the wound (s = 49) from 36 cats, and the remaining seven cats had all the three types of samples collected from the infected area of their body. All the collected samples were then brought to the Veterinary Bacteriology Laboratory, UPM, for a fungal culture procedure.

Sample Inoculation

Sabouraud Dextrose Agar (SDA) media supplemented with 0.5% chloramphenicol (Merck, Germany) and cycloheximide (Merck, Germany) were used to inoculate all the samples. Each sample was inoculated in duplicate onto the SDA media. All the inoculated plates were then incubated at room temperature for 1–4 weeks with daily observation. It is recommended to incubate the plates at 25–27°C in an inverted position to avoid contamination (Moriello et al., 2017). The inoculation of the collected samples showed positive growth of fungal culture from hair plucked from 49 cats, skin scraping (n = 16 cats), swab of wound (n = 22 cats), and other six cats with all the three types of samples taken from the infected area of their body.

Fungal Culture Identification

The fungal cultures were identified through two measures: (1) the macroscopic and (2) the microscopic observations for the genus identification and molecular method by polymerase chain reaction (PCR) to determine the fungal species. The colony's structure, texture, and colour were observed for macroscopic identification before proceeding with microscopic observation using lactophenol cotton blue stain and glass slide. The morphological evaluations of the fungal culture were based on the key taxonomy (Ellis et al., 2007) and the references from the International Society for Human and Animal Mycology (ISHAM) database.

Subcultures were conducted after the species identification to obtain the pure colony of the culture before proceeding to PCR. The DNA of the fungal colonies was extracted using the DNeasy Ultraclean Microbial Kit (QIAGEN, Germany) following the manufacturer's protocol. Two sets of primer sequences used were internal transcribed spacer regions (*ITS1* and *ITS4*) (Ferrer et al., 2001) and the *β-tubulin* gene (*Bt2a* and *Bt2b*) (Gupta et al., 2000). A total of 25 µl per reaction was used with the amplification of PCR at 94°C for 5 min, 35 cycles of denaturation at 94°C for 45 s, annealing at 55°C for 45 s, and extension at 72°C for 60 s, followed by cycle at 72°C for 7 min completed in a thermal cycler (Eppendorf™, Germany). Gel electrophoresis was conducted using 1.5% agarose gel and visualised under UV light transilluminator light cabinet gel documentation. The PCR products were

then sent to the sequencing service, and the gene sequences were blasted in the National Centre of Biotechnology Information (NCBI) to determine the fungal species.

RESULTS

Identification of *M. canis* and *S. schenckii*

For *M. canis*, the colony is flat and spreading; the surface is white to cream coloured with a fluffy or cottony texture on the surface and bright yellow to brownish-yellow pigment on the periphery but sometimes non-pigmented (Figure 1), similar to reverse morphology (Figure 2) (Ellis et al., 2007). The microscopic observation showed septate hyphae with numerous macroconidia in spindle-shaped (5–15 cells) (Figure 3),

verrucose thick-walled with a terminal knob. Only a few microconidia were presented in pyriform to clavate shape (Ellis et al., 2007).

For *S. schenckii*, the colony morphology at room temperature (25–27°C) is small and white with no hyphae. Since it is a growth culture, the colony slowly becomes moist after a week, wrinkled (Figures 4 and 5) may produce short aerial hyphae, and the pigmentation varies from white to cream, then darker to brownish or black (Ellis et al., 2007). The microscopic morphology of *S. schenckii* is septate hyphae and branching with many small conidia pear-shaped, where the arrangement sometimes forms a flower or ‘rosette-like’ (Figure 6) (Ellis et al., 2007). The conidia are elongated, one-celled, and smooth-walled (Ellis et al., 2007).

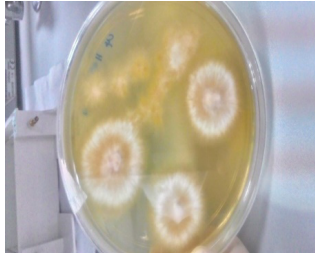

Figure 1. *Microsporium canis* colony morphology observed on Sabouraud Dextrose Agar media from the sample collected in this study

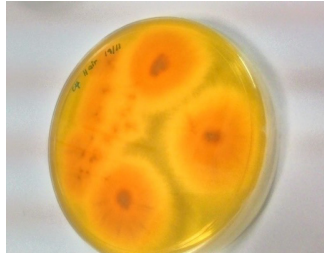


Figure 2. *Microsporium canis* reverse colony morphology on Sabouraud Dextrose Agar

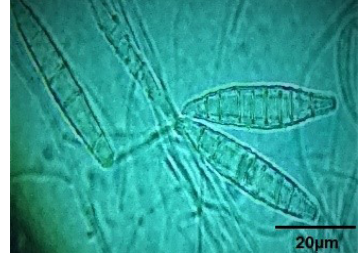


Figure 3. Photomicrograph of macroconidia of *Microsporium canis* stained with lactophenol cotton blue

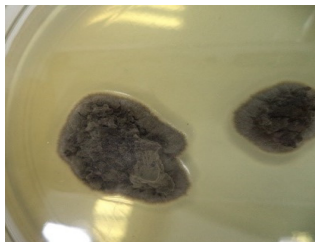

Figure 4. *Sporothrix schenckii* top colony morphology on Sabouraud Dextrose Agar

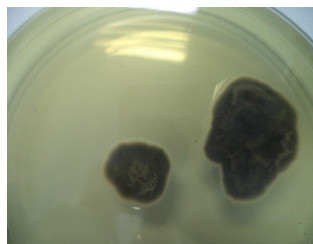


Figure 5. *Sporothrix schenckii* reverse colony morphology observed on Sabouraud Dextrose Agar media

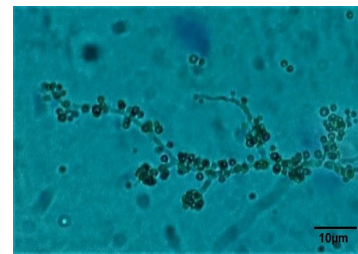


Figure 6. Photomicrograph of *Sporothrix schenckii* stained with lactophenol cotton blue

Fungal Species Identified from Collected Samples

Out of 127 cats, 93 cats were positive for skin fungal infections. Of the 93 infected cats, 35 were solely infected with *M. canis*; one was infected with *M. canis* and *S. schenckii* infections from the samples inoculated, and the remaining two were infected by saprophytic fungi, such as *Penicillium* sp. and *Fusarium* sp. simultaneously with *M. canis*. *Microsporium canis* were highly isolated from the hair-plucked samples (n = 30 cats) and skin scraping (n = 8 cats).

Out of 38 cats infected with *M. canis*, most cats infected were domestic breed (n = 20), followed by British Shorthair (n = 4), British Longhair (n = 1), Persian (n = 3), American Shorthair (n = 1), Balinese (n = 1), Munchkin cross (n = 1), Siamese breed (n = 1), and not stated (n = 6). Although long-haired breed cats, such as Persian cats, have a higher tendency to get infected with ringworms compared to other breeds (Bond, 2010), the condition of the environment also influences the growth of dermatophytes (Chermette et al., 2008). Animals can also carry the fungal spores without having any

signs of infection on the animal's body (Chermette et al., 2008). This statement is echoed by Ilhan et al. (2016) and Nichita and Marcu (2010), where some cats were known to be a reservoir for *M. canis* as they did not show any visible lesions, thus becoming transient carrier cats.

However, *S. schenckii* infecting cats (n = 26) were mostly collected from swabs of ulcerated wounds. A total of 21 out of 26 cats were solely infected with *S. schenckii*. In comparison, the remaining five infected cats showed mixed infection with other fungal species, such as *Talaromyces* sp., *Penicillium* sp., *Curvularia* sp., and *Trichosporon* sp. The other remaining samples collected from 29 cats showed *Aspergillus* sp., *Chaetomium* sp., *Chrysosporium* sp., *Curvularia* sp., *Cladosporium* sp., *Fusarium* sp., *Geotrichum* sp., *Penicillium* sp., *Talaromyces* sp., and yeast.

Tables 1 and 2 present the fungal species found from the sampled cats in the Central Region of Peninsular Malaysia, identified using direct examination and molecular diagnosis.

Table 1

A single colony of fungal species from the sampled cats in the Central Region of Peninsular Malaysia

Fungal species	Number of cats (n)	Fungal species	Number of cats (n)
<i>Alternaria</i> sp.	1	<i>Curvularia</i> sp.	1
<i>Aspergillus</i> sp.	3	<i>Fusarium</i> sp.	1
<i>Candida</i> sp.	2	<i>Geotrichum</i> sp.	1
<i>Chaetomium</i> sp.	4	<i>Microsporium canis</i>	35
<i>Chrysosporium</i> sp.	1	<i>Penicillium</i> sp.	3
<i>Cladosporium</i> sp.	1	<i>Sporothrix schenckii</i>	21
<i>Cryptococcus</i> sp.	1		

Table 1 (Continue)

Fungal species	Number of cats (n)
<i>Trichoderma</i> sp.	1
<i>Xenomyrothecium</i> sp.	1
<i>Xylaria</i> sp.	1
Yeast	2

Note. List of fungal species identified by direct examination method and (n) indicates the number of infected cats in this study

DISCUSSION

Dermatophytosis is a skin disease caused by a superficial fungal infection invading the keratinised tissues of the hosts by zoophilic, geophilic, or anthropophilic fungal organisms, mainly *M. canis*, *Microsporium gypseum*, and *Trichophyton mentagrophytes* (Moriello, 2004; Moriello et al., 2017; Paryuni et al., 2020). The results revealed that *M. canis* is a common fungal species that infect cats easily. A study conducted by Nichita and Marcu (2010) found that *M. canis* is the most prevalent fungal species observed from skin lesions and fur collected from cats (26.7%) and dogs (16.8%). From the sample collected, hair plucked, and skin scraping from the infected cats found many *M. canis* when the samples were cultured on SDA media. The prevalence of dermatophytes in cats is usually higher by 20% compared to dogs (Nichita & Marcu, 2010). This fungal species grows after 4 to 7 days of inoculation. Chermette et al. (2008) stated that ringworm is one of the most occurring skin mycoses among pets and livestock. In addition, the infection is usually characterised by cutaneous lesions on the animals' skin, hair, and nails (Paixão et al., 2001).

Table 2

Mix fungal species on the sampled cats in the Central Region of Peninsular Malaysia

Multiple fungal species infecting the sampled cats	Number of cats (n)
<i>Aspergillus</i> sp. and <i>Curvularia</i> sp.	1
<i>Chrysosporium</i> sp. and <i>Cladosporium</i> sp.	1
<i>Curvularia</i> sp. and <i>Cladosporium</i> sp.	1
<i>Microsporium canis</i> and <i>Penicillium</i> sp.	1
<i>Microsporium canis</i> and <i>Sporothrix schenckii</i>	1
<i>Microsporium canis</i> , <i>Fusarium</i> sp., and <i>Penicillium</i> sp.	1
<i>Penicillium</i> sp. and <i>Aspergillus</i> sp.	1
<i>Penicillium</i> sp. and <i>Cladosporium</i> sp.	1
<i>Sporothrix schenckii</i> and <i>Curvularia</i> sp.	1
<i>Sporothrix schenckii</i> and <i>Penicillium</i> sp.	1
<i>Sporothrix schenckii</i> and <i>Talaromyces</i> sp.	2
<i>Sporothrix schenckii</i> and <i>Trichosporon</i> sp.	1

Note. List of fungal species identified by direct examination method and (n) indicates the number of infected cats in this study

Furthermore, this study found that 15 out of 38 infected cats were young cats under one year old. According to Paixão et al. (2001), animals that are below a year old are susceptible to dermatophytoses. This study also observed that the number of male and female cats infected was almost equal. This result is in line with the previous study by Paixão et al. (2001),

which claimed that gender does not influence fungal infection. Other studies stated that hair coat, sex, age, season of sampling, and geographical condition did not show any significant association with the prevalence of dermatophyte (Proverbio et al., 2014). Nevertheless, the transmission of dermatophytes can occur when cats are exposed to the environment and have contact with infected hair or fomites from clippers and brushes (Ilhan et al., 2016). In this study, the number of infected cats that frequently went for grooming was high, 24 out of 38.

Apart from dermatophytosis, *S. schenckii* recorded many fungal infections that caused dermatitis in the sampled cats. Twenty-six (26) cats were positive for *S. schenckii*, where 21 were pure culture, and the remaining four were a combination of *S. schenckii* with other saprophytic fungi. All cats sampled showed ulcerated lesions on their body parts. Siew (2017) stated that feline sporotrichosis has been reported in Malaysia since the 1990s. Thus, since then, he revealed that *S. schenckii sensu stricto* clinical clade D of single strain is Malaysia's most common cause of sporotrichosis (Siew, 2017). Before that, the *S. schenckii* clinical clade C and D were reported to be commonly found in human sporotrichosis in Asia (Kano et al., 2015).

Sporotrichosis is caused by the dimorphic fungus, *S. schenckii*, which can be present in two forms: (1) yeast form when invaded the host body (body temperature state) and (2) mycelial form at environmental temperature, thus capable of infecting dogs and cats and other mammalians species,

including horses, camels, cattle, and swine (Lloret et al., 2013). According to Spickler (2017), sporotrichosis is contagious in cats as an abundance of yeasts can be found in skin lesions, and this organism can enter the body. However, there is only a tiny amount of damage or even undamaged on the skin. Cutaneous, lymphocutaneous and disseminated forms were the three clinical forms of sporotrichosis in cats (Lloret et al., 2013; T. M. P. Schubach et al., 2004). Cats suffer sporotrichosis in the cutaneous form usually have multiple, ulcerated and crusted nodules, draining tracts and abscesses or cellulitis on the common areas of bites and scratching during fights, which is the head, limbs and tail-base region (Lloret et al., 2013; Reis et al., 2012). In addition, most cases of cutaneous forms arise from hematogenous spread, while lymphatic form can be seen through histology can be either biopsies or necropsy samples (Crothers et al., 2009; Lloret et al., 2013; Welsh, 2003). Other than that, dissemination may occur via inoculation during grooming, where spores enter through cuts in the skin (Crothers et al., 2009; Leme et al., 2007; Lloret et al., 2013; T. M. P. Schubach et al., 2004). Nevertheless, systemic or disseminated sporotrichosis was rarely observed in humans and animals and was often only associated with host immunodeficiency status (Duangkaew et al., 2019; Rodrigues et al., 2013).

In this study, a cat got a wound after being hit by a car, and four cats had a history of sporotrichosis. Late treatment of a prolonged unhealing wound might also become the factor that causes the spreading

or complication of the infection. The irregularity of treatment and missing the follow-up could delay the recovery process and worsen the condition (Chaves et al., 2013). Several factors contribute to the low percentage of recovery in sporotrichosis among cats, such as irregular administration of medications, difficulty administering oral medication, and increased virulence of the fungal species (da Santos Silva et al., 2018). In addition, the recurrence might occur as some cats did not always respond to the treatment (Gremião et al., 2014). Furthermore, the chances for the reactivation of the lesions are also high despite the end of treatment (Chaves et al., 2013; Gremião et al., 2011, 2014; Pereira et al., 2010). Hirano et al. (2006) stated that medication should be continuously given for one to two months after the cat appeared clinically normal to avoid reappearing and failure of the treatment. Besides, the host's immune response is also important to avoid recurrent infection (Siew et al., 2017).

This study observed that 20 out of 26 cats were male. Based on other studies, diseases in cats, such as sporotrichosis, were reported mostly in free-roaming intact males (Lloret et al., 2013). From the data collected, 21 cats have free access outside their house. It might be the factor that causes the cats to get infected with sporotrichosis, as the fungus species can be found in contaminated environments, such as living and dead vegetation (Kano et al., 2015). In addition, *S. schenckii* can be isolated from skin lesions, claws, and nasal and oral cavities (Lloret et al., 2013; Spickler, 2017). The data in this study revealed that out of 26 infected

cats, one got the infection from another cat suffering from sporotrichosis reared in the same house. Based on several studies, cats get the infection through scratches and bites transmitted from infected cats (Kano et al., 2015; Lloret et al., 2013; Siew, 2017; Spickler, 2017). In Malaysia, *S. schenckii* is the main species causing sporotrichosis in cats, while *S. globosa* is extensively reported in other Asian countries as the main cause (Moussa et al., 2017).

The hair of animals is a collector of environmental fungi where indoor pets are easily contaminated by air-borne fungi (Aho, 1983). Nevertheless, a study by Aho (1983) also stated that the spreading of fungal flora indoors or outdoors is not constant and varies sporadically. From this study, 37 sampled cats showed the growth of saprophytic fungi species from the inoculated samples, with 13 of the cats having mixed colonies of fungal species, with some showing a combination with *M. canis* and *S. schenckii*. The genera of the saprobe fungi were *Alternaria* sp., *Aspergillus* sp., *Byssochlamys* sp., *Chaetomium* sp., *Chrysosporium* sp., *Cladosporium* sp., *Curvularia* sp., *Fusarium* sp., *Geotrichum* sp., *Penicillium* sp., *Talaromyces* sp., *Trichoderma* sp., and *Xylaria* sp. This study also observed yeast genera infected five cats: *Candida* sp., *Trichosporon* sp., and two other unidentified yeast.

The genus of *Talaromyces* is introduced as the teleomorph of *Penicillium* sp. (Yilmaz et al., 2014). This genus was reported as endemic in most rural areas in Southeast Asian countries and commonly found in contaminated soil, causing pulmonary

infection in immunocompromised humans and bamboo rats (Kauffman, 2017). Some species within the *Talaromyces* genus, such as *Talaromyces marneffeii*, are known to cause pneumonia in a dog from Southern Brazil (Headley et al., 2017), while *Talaromyces helices* cause granulomatous lymphadenitis in the dog (Tomlinson et al., 2011). Other than that, *Aspergillus* sp., *Penicillium* sp., *Alternaria* sp., *Mucor* sp., and *Fusarium* sp. are the common saprobe fungi frequently found isolated on the skin of cats and dogs with dermatophytes infections caused by contact with contaminated soil, air, and plants (Paixão et al., 2001; Stojanov et al., 2009). Besides, *Aspergillus* sp., *Penicillium* sp., and *Talaromyces* sp. were recognised as indoor microbiota as they can be found in dust samples in houses worldwide (Visagie et al., 2014) while *Cladosporium* sp. are common fungi that can be found worldwide, in outdoor and indoor air and frequently encountered as secondary invaders contaminants (Bensch et al., 2018; Sandoval-Denis et al., 2015). *Fusarium* sp. has been reported to cause mycetoma, keratomycosis, and onychomycosis in humans (Kano et al., 2002). In contrast, *Curvularia lunata* causes diseases in plants, animals, and humans, and the severity level varies among patients, thus making it a public health concern (Bengyella et al., 2017).

From this study, the cats with the saprophytic fungi species growing together with dermatophyte and *S. schenckii* from their inoculated samples might be because of the contaminated environment around them, as 78 of the total sampled cats stayed

indoors. Other than that, there were two cats infected with *Chrysosporium* sp. Although *Chrysosporium* sp. is often considered a contaminant since it is saprophytic fungi from soil, the clinical symptoms were similar to dermatophytes infection, causing misdiagnosis of the species (Dokuzeylul et al., 2013).

As dermatophytosis and sporotrichosis are zoonotic (Seyedmousavi et al., 2015, 2018), it can easily be transmitted from animals to humans naturally since cats and dogs have a close relationship with human beings as both animals are known to be the most popular among pets. Therefore, zoonotic fungal infections have become a public health concern (Seyedmousavi et al., 2018). A study conducted in Italy stated that cats and dogs should be considered the primary source of pathogenic dermatophytes for humans. However, they do not present any clinical signs of dermatophytosis, where the risk of transmission of *M. canis* to humans is higher in asymptomatic cats compared to asymptomatic dogs (Cafarchia et al., 2006; Mancianti et al., 2003). Besides, the household environment can be contaminated with *M. canis* through either asymptomatic *M. canis* carriers or symptomatic animals, which is risky to human health (Mancianti et al., 2003). Since *M. canis* known as a worldwide zoophilic and zoonotic dermatophyte, these isolates that are commonly in cats and dogs can easily be pathogenic and highly contagious to humans (Müştak et al., 2019; Šubelj et al., 2014). In addition, this zoophilic species lives in close association with animals other than humans, and the

transmission to humans usually occurs through the reservoirs, where dermatophyte fungi can occur either symptomatically or asymptotically in the fur of animal hosts. It can become an epidemic (de Hoog et al., 2017). Another author also mentioned that *M. canis* from cats, dogs, horses, and all other mammals give high zoonotic risk to humans (Hubka et al., 2018).

Sporotrichosis also has become an important dimorphic fungal infection as it is zoonotic, and humans can acquire it via scratches and bites from infected cats (A. Schubach et al., 2008; Gremião et al., 2017; Siew, 2017; Tang et al., 2012). Although there were only 12 cases of zoonotic sporotrichosis were reported from 1990 to 2010 (Tang et al., 2012; Zamri-Saad et al., 1990), unpublished data by Chan and Selvarajah (2013) recorded that feline sporotrichosis cases showed an increased trend from 2008 to 2012 with 80 feline sporotrichosis cases per year in the state of Selangor. It could be speculated that the increase in feline sporotrichosis cases possibly led to increase human cases from cat scratches and bites (Azam et al., 2019).

Despite the devastating fungal infection, especially seen in sporotrichosis, most fungal contaminants are known to be harmless to healthy humans and animals. However, if the infection becomes invasive in a condition that reduces the body's resistance to fight against infections, it can become pathogenic to the host (Aho, 1983; Paixão et al., 2001). Thus, when involved with saprobe fungi in handling mycoses in cats, it is crucial to differentiate the pathogenic fungi contributing to the infections.

CONCLUSION

Fungal infections can affect cats through direct contact with the contaminated environment or contact with the infected cats. The infected cats should be treated right away after being diagnosed. For future studies, the questionnaire regarding the management of the cats should be more precise so that the risk factors can be analysed. Besides, the sampling area can be widened to measure the prevalence of skin mycoses among cats in Malaysia.

ACKNOWLEDGEMENTS

This research project is part of a research study undertaken by the Faculty of Veterinary Medicine, Universiti Putra Malaysia (UPM) and was funded by the UPM research grant (GP-IPM/2018/9585800). This study has also been approved by the Institutional Animal Care and Use Committee (IACUC), UPM (UPM/IACUC/AUP-R001/2019).

REFERENCES

- Aho, R. (1983). Saprophytic fungi isolated from the hair of domestic and laboratory animals with suspected dermatophytosis. *Mycopathologia*, 83, 65-73. <https://doi.org/10.1007/BF00436886>
- Azam, N. K. K., Selvarajah, G. T., Santhanam, J., Abdul Razak, M. F., Ginsapu, S. J., James, J. E., & Suetrong, S. (2019). Molecular epidemiology of *Sporothrix schenckii* isolates in Malaysia. *Medical Mycology*, 61(6), 617-625. <https://doi.org/10.1093/mmy/myz106>
- Bengyella, L., Yekwa, L. E., Waikhom, S. D., Nawaz, K., Iftikhar, S., Motloi, T. S., Tambo, E., & Roy, P. (2017). Upsurge in *Curvularia* infections and global emerging antifungal drug resistance. *Asian Journal of Scientific Research*, 10(4), 299-307. <https://doi.org/10.3923/ajsr.2017.299.307>

- Bensch, K., Groenewald, J. Z., Meijer, M., Dijkstehuis, J., Jurjević, Ž., Andersen, B., Houbraken, J., Crous, P. W., & Samson, R. A. (2018). *Cladosporium* species in indoor environments. *Studies in Mycology*, *89*, 177-301. <https://doi.org/10.1016/j.simyco.2018.03.002>
- Bond, R. (2010). Superficial veterinary mycoses. *Clinics in Dermatology*, *28*(2), 226–236. <https://doi.org/10.1016/j.clindermatol.2009.12.012>
- Cafarchia, C., Romito, D., Capelli, G., Guillot, J., & Otranto, D. (2006). Isolation of *Microsporum canis* from the hair coat of pet dogs and cats belonging to owners diagnosed with *M. canis* tinea corporis. *Veterinary Dermatology*, *17*(5), 327–331. <https://doi.org/10.1111/j.1365-3164.2006.00533.x>
- Chan, W. Y., & Selvarajah, G. T. (2013, August 23-24). *Retrospective case series of feline sporotrichosis diagnosed in a veterinary teaching hospital in Malaysia from 2008 to 2012* [Paper presentation]. Malaysian Small Animal Veterinary Association National Scientific Conference, Kuala Lumpur, Malaysia.
- Chaves, A. R., de Campos, M. P., Barros, M. B. L., do Carmo, C. N., Gremião, I. D. F., Pereira, S. A., & Schubach, T. M. P. (2013). Treatment abandonment in feline sporotrichosis - Study of 147 cases. *Zoonoses and Public Health*, *60*(2), 149–153. <https://doi.org/10.1111/j.1863-2378.2012.01506.x>
- Chermette, R., Ferreiro, L., & Guillot, J. (2008). Dermatophytoses in animals. *Mycopathologia*, *166*, 385–405. <https://doi.org/10.1007/s11046-008-9102-7>
- Crothers, S. L., White, S. D., Ihrke, P. J., & Affolter, V. K. (2009). Sporotrichosis: A retrospective evaluation of 23 cases seen in northern California (1987-2007). *Veterinary Dermatology*, *20*(4), 249–259. <https://doi.org/10.1111/j.1365-3164.2009.00763.x>
- da Santos Silva, F., do Santos Cunha, S. C., de Souza Baptista, A. R., dos Santos Baptista, V., da Silva, K. V. G. C., Coêlho, T. F. Q., & Ferreira, A. M. R. (2018). Miltefosine administration in cats with refractory sporotrichosis. *Acta Scientiae Veterinariae*, *46*(1), 7. <https://doi.org/10.22456/1679-9216.83639>
- de Hoog, G. S., Dukik, K., Monod, M., Packeu, A., Stubbe, D., Hendrickx, M., Kupsch, C., Stielow, J. B., Freeke, J., Göker, M., Rezaei-Matehkolaei, A., Mirhendi, H., & Gräser, Y. (2017). Toward a novel multilocus phylogenetic taxonomy for the dermatophytes. *Mycopathologia*, *182*, 5–31. <https://doi.org/10.1007/s11046-016-0073-9>
- Debra, M., Mastura, Y., Shariffah, N., Muhammad Nazri, K., Azjeemah Bee, S.H., Sharil Azwan, M. Z., & Fakhrolisham, R. (2019). Assessing the status of pet ownership in the community of Putrajaya. *Malaysian Journal of Veterinary Research*, *10*(1), 61-71.
- Dokuzeylül, B., Basaran Kahraman, B., Sigirci, B. D., Gulluoglu, E., Metiner, K., & Or, M. E. (2013). Dermatophytosis caused by a *Chrysosporium* species in two cats in Turkey: A case report. *Veterinarni Medicina*, *58*(12), 633–646. <https://doi.org/10.17221/7187-VETMED>
- Duangkaew, L., Yurayart, C., Limsivilai, O., Chen, C., & Kasorndorkbua, C. (2019). Cutaneous sporotrichosis in a stray cat from Thailand. *Medical Mycology Case Reports*, *23*, 46–49. <https://doi.org/10.1016/j.mmcr.2018.12.003>
- Ellis, D., Davis, S., Alexiou, H., Handke, R., & Bartley, R. (2007). *Descriptions of medical fungi*. University of Adelaide Press.
- Ferrer, C., Colom, F., Frases, S., Mulet, E., Abad, J. L., & Alió, J. L. (2001). Detection and identification of fungal pathogens by PCR and by ITS2 and 5.8S ribosomal DNA typing in ocular infections. *Journal of Clinical Microbiology*, *39*(8), 2873–2879. <https://doi.org/10.1128/JCM.39.8.2873-2879.2001>
- Gremião, I. D. F., Menezes, R. C., Schubach, T. M. P., Figueiredo, A. B. F., Cavalcanti, M. C. H., & Pereira, S. A. (2014). Feline sporotrichosis: Epidemiological and clinical aspects. *Medical Mycology*, *53*(1), 15–21. <https://doi.org/10.1093/mmy/myu061>

- Gremião, I. D. F., Miranda, L. H. M., Reis, E. G., Rodrigues, A. M., & Pereira, S. A. (2017). Zoonotic epidemic of sporotrichosis: Cat to human transmission. *PLOS Pathogens*, *13*(1), e1006077. <https://doi.org/10.1371/journal.ppat.1006077>
- Gremião, I. D. F., Schubach, T. M. P., Pereira, S. A., Rodrigues, A. M., Honse, C. O., & Barros, M. B. L. (2011). Treatment of refractory feline sporotrichosis with a combination of intralesional amphotericin B and oral itraconazole. *Australian Veterinary Journal*, *89*(9), 346–351. <https://doi.org/10.1111/j.1751-0813.2011.00804.x>
- Gupta, A. K., Kohli, Y., & Summerbell, R. C. (2000). Molecular differentiation of seven *Malassezia* species. *Journal of Clinical Microbiology*, *38*(5), 1869–1875. <https://doi.org/10.1128/jcm.38.5.1869-1875.2000>
- Headley, S. A., Pretto-Giordano, L. G., Lima, S. C., Suhett, W. G., Pereira, A. H. T., Freitas, L. A., Suphoronski, S. A., Oliveira, T. E. S., Alfieri, A. F., Pereira, E. C., Vilas-Boas, L. A., & Alfieri, A. A. (2017). Pneumonia due to *Talaromyces marneffeii* in a dog from Southern Brazil with concomitant canine distemper virus infection. *Journal of Comparative Pathology*, *157*(1), 61–66. <https://doi.org/10.1016/j.jcpa.2017.06.001>
- Hirano, M., Watanabe, K., Murakami, M., Kano, R., Yanai, T., Yamazoe, K., Fukata, T., & Kudo, T. (2006). A case of feline sporotrichosis. *Journal of Veterinary Medical Science*, *68*(3), 283–284. <https://doi.org/10.1292/jvms.68.283>
- Hubka, V., Peano, A., Cmokova, A., & Guillot, J. (2018). Common and emerging dermatophytoses in animals: Well-known and new threats. In S. Seyedmousavi, G. de Hoog, J. Guillot, & P. Verweij (Eds.), *Emerging and epizootic fungal infections in animals* (pp. 31–79). Springer. https://doi.org/10.1007/978-3-319-72093-7_3
- Ilhan, Z., Karaca, M., Ekin, I. H., Solmaz, H., Akkan, H. A., & Tutuncu, M. (2016). Detection of seasonal asymptomatic dermatophytes in Van cats. *Brazilian Journal of Microbiology*, *47*(1), 225–230. <https://doi.org/10.1016/j.bjm.2015.11.027>
- Kano, R., Okayama, T., Hamamoto, M., Nagata, T., Ohno, K., Tsujimoto, H., Nakayama, H., Doi, K., Fujiwara, K., & Hasegawa, A. (2002). Isolation of *Fusarium solani* from a dog: Identification by molecular analysis. *Medical Mycology*, *40*(4), 435–437. <https://doi.org/10.1080/mmy.40.4.435.437>
- Kano, R., Okubo, M., Siew, H. H., Kamata, H., & Hasegawa, A. (2015). Molecular typing of *Sporothrix schenckii* isolates from cats in Malaysia. *Mycoses*, *58*(4), 220–224. <https://doi.org/10.1111/myc.12302>
- Kauffman, C. A. (2017). Fungal pneumonias. In J. Cohen, W. G. Powderly, & S. M. Opal (Eds.), *Infectious diseases* (4th ed., Vol. 1, pp. 292–299. e1). Elsevier. <https://doi.org/10.1016/b978-0-7020-6285-8.00033-2>
- Leme, L. R. P., Schubach, T. M. P., Santos, I. B., Figueiredo, F. B., Pereira, S. A., Reis, R. S., Mello, M. F. V., Ferreira, A. M. R., Quintella, L. P., & Schubach, A. O. (2007). Mycological evaluation of bronchoalveolar lavage in cats with respiratory signs from Rio de Janeiro, Brazil. *Mycoses*, *50*(3), 210–214. <https://doi.org/10.1111/j.1439-0507.2007.01358.x>
- Lim, A. (2002, January 15). The six regions of Malaysia. *ThingsAsian*. <http://thingsasian.com/story/six-regions-malaysia>
- Lloret, A., Hartmann, K., Pennisi, M. G., Ferrer, L., Addie, D., Belák, S., Boucraut-Baralon, C., Egberink, H., Frymus, T., Gruffydd-Jones, T., Hosie, M. J., Lutz, H., Marsilio, F., Möstl, K., Radford, A. D., Thiry, E., Truyen, U., & Horzinek, M. C. (2013). Sporotrichosis in cats: ABCD guidelines on prevention and management. *Journal of Feline Medicine and Surgery*, *15*(7), 619–623. <https://doi.org/10.1177/1098612X13489225>
- Mancianti, F., Nardoni, S., Corazza, M., D’Achille, P., & Ponticelli, C. (2003). Environmental detection of *Microsporium canis* arthrospores in the households of infected cats and dogs. *Journal of Feline Medicine and Surgery*, *5*(6), 323–328. [https://doi.org/10.1016/S1098-612X\(03\)00071-8](https://doi.org/10.1016/S1098-612X(03)00071-8)

- Moriello, K. A. (2004). Treatment of dermatophytosis in dogs and cats: Review of published studies. *Veterinary Dermatology*, 15(2), 99-107. <https://doi.org/10.1111/j.1365-3164.2004.00361.x>
- Moriello, K. A., Coyner, K., Paterson, S., & Mignon, B. (2017). Diagnosis and treatment of dermatophytosis in dogs and cats: Clinical consensus guidelines of the World Association for Veterinary Dermatology. *Veterinary Dermatology*, 28, 266-e68. <https://doi.org/10.1111/vde.12440>
- Moussa, T. A. A., Kadasa, N. M. S., Al Zahrani, H. S., Ahmed, S. A., Feng, P., van den Ende, A. H. G. G., Zhang, Y., Kano, R., Li, F., Li, S., Song, Y., Dong, B., Rossato, L., Dolatabadi, S., & de Hoog, S. (2017). Origin and distribution of *Sporothrix globosa* causing sapronoses in Asia. *Journal of Medical Microbiology*, 66(5), 560–569. <https://doi.org/10.1099/jmm.0.000451>
- Müştak, İ. B., Sariçam, S., & Müştak, H. K. (2019). Comparison of internal transcribed spacer region sequencing and conventional methods used in the identification of fungi isolated from domestic animals. *Kafkas Üniversitesi Veteriner Fakültesi Dergisi*, 25(5), 639–643. <https://doi.org/10.9775/kvfd.2018.21506>
- Nichita, I., & Marcu, A. (2010). The fungal microbiota isolated from cats and dogs. *Scientific Papers Animal Science and Biotechnologies*, 43(1), 411–414.
- Paixão, G. C., Sidrim, J. J. C., Campos, G. M. M., Brillhante, R. S. N., & Rocha, M. F. G. (2001). Dermatophytes and saprobe fungi isolated from dogs and cats in the city of Fortaleza, Brazil. *Arquivo Brasileiro de Medicina Veterinária e Zootecnia*, 53(5), 568–573. <https://doi.org/10.1590/S0102-09352001000500010>
- Paryuni, A. D., Indarjulianto, S., & Widyarini, S. (2020). Dermatophytosis in companion animals: A review. *Veterinary World*, 13(6), 1174–1181. <https://doi.org/10.14202/vetworld.2020.1174-1181>
- Pereira, S. A., Passos, S. R. L., Silva, J. N., Gremião, I. D. F., Figueiredo, F. B., Teixeira, J. L., Monteiro, P. C. F., & Schubach, T. M. P. (2010). Response to azolic antifungal agents for treating feline sporotrichosis. *Veterinary Record*, 166(10), 290–294. <https://doi.org/10.1136/vr.166.10.290>
- Proverbio, D., Perego, R., Spada, E., de Giorgi, G. B., Pepa, A. D., & Ferro, E. (2014). Survey of dermatophytes in stray cats with and without skin lesions in northern Italy. *Veterinary Medicine International*, 2014, 565470. <https://doi.org/10.1155/2014/565470>
- Reis, É. G., Gremião, I. D. F., Kitada, A. A. B., Rocha, R. F. D. B., Castro, V. S. P., Barros, M. B. L., Menezes, R. C., Pereira, S. A., & Schubach, T. M. P. (2012). Potassium iodide capsule treatment of feline sporotrichosis. *Journal of Feline Medicine and Surgery*, 14(6), 399–404. <https://doi.org/10.1177/1098612X12441317>
- Rodrigues, A. M., de Melo Teixeira, M., de Hoog, G. S., Schubach, T. M. P., Pereira, S. A., Fernandes, G. F., Bezerra, L. M. L., Felipe, M. S., & de Camargo, Z. P. (2013). Phylogenetic analysis reveals a high prevalence of *Sporothrix brasiliensis* in feline sporotrichosis outbreaks. *PLOS Neglected Tropical Diseases*, 7(6), e2281. <https://doi.org/10.1371/journal.pntd.0002281>
- Sandoval-Denis, M., Sutton, D. A., Martin-Vicente, A., Cano-Lira, J. F., Wiederhold, N., Guarro, J., & Gené, J. (2015). *Cladosporium* species recovered from clinical samples in the United States. *Journal of Clinical Microbiology*, 53(9), 2990–3000. <https://doi.org/10.1128/JCM.01482-15>
- Schubach, A., de Lima Barros, M. B., & Wanke, B. (2008). Epidemic sporotrichosis. *Current Opinion in Infectious Diseases*, 21(2), 129–133. <https://doi.org/10.1097/QCO.0b013e3282f44c52>
- Schubach, T. M. P., Schubach, A., Okamoto, T., Barros, M. B. L., Figueiredo, F. B., Cuzzi, T., Fialho-Monteiro, P. C., Reis, R. S., Perez, M. A., & Wanke, B. (2004). Evaluation of an epidemic of sporotrichosis in cats: 347 cases (1998–2001). *Journal of the American Veterinary Medical Association*, 224(10), 1623–1629. <https://doi.org/10.2460/javma.2004.224.1623>

- Seyedmousavi, S., de M. G. Bosco, S., de Hoog, S., Ebel, F., Elad, D., Gomes, R. R., Jacobsen, I. D., Martel, A., Mignon, B., Pasmans, F., Piecková, E., Rodrigues, A. M., Singh, K., Vicente, V. A., Wibbelt, G., Wiederhold, N. P., & Guillot, J. (2018). Corrigendum: Fungal infections in animals: A patchwork of different situations. *Medical Mycology*, 56(8), e4. <https://doi.org/10.1093/mmy/myy028>
- Seyedmousavi, S., Guillot, J., Tolooe, A., Verweij, P. E., & de Hoog, G. S. (2015). Neglected fungal zoonoses: Hidden threats to man and animals. *Clinical Microbiology and Infection*, 21(5), 416-425. <https://doi.org/10.1016/j.cmi.2015.02.031>
- Siew, H. H. (2017). The current status of feline sporotrichosis in Malaysia. *Medical Mycology Journal*, 58(3), E107–E113. <https://doi.org/10.3314/mmj.17.014>
- Spickler, A. R. (2017). *Sporotrichosis*. <https://www.cfsph.iastate.edu/Factsheets/pdfs/sporotrichosis.pdf>
- Stojanov, I. M., Prodanov, J. Z., Pušić, I. M., & Ratajac, R. D. (2009). Dermatormycosis: A potential source of zoonotic infection in cities. *Zbornik Matice Srpske za Prirodne Nauke*, 116, 275-280. <https://doi.org/10.2298/ZMSPN0916275S>
- Šubelj, M., Marinko, J. S., & Učakar, V. (2014). An outbreak of *Microsporium canis* in two elementary schools in a rural area around the capital city of Slovenia, 2012. *Epidemiology and Infection*, 142(12), 2662–2666. <https://doi.org/10.1017/S0950268814000120>
- Tang, M. M., Tang, J. J., Gill, P., Chang, C. C., & Baba, R. (2012). Cutaneous sporotrichosis: A six-year review of 19 cases in a tertiary referral center in Malaysia. *International Journal of Dermatology*, 51(6), 702–708. <https://doi.org/10.1111/j.1365-4632.2011.05229.x>
- Tomlinson, J. K., Cooley, A. J., Zhang, S., & Johnson, M. E. (2011). Granulomatous lymphadenitis caused by *Talaromyces helicus* in a Labrador Retriever. *Veterinary Clinical Pathology*, 40(4), 553–557. <https://doi.org/10.1111/j.1939-165X.2011.00377.x>
- Visagie, C. M., Hirooka, Y., Tanney, J. B., Whitfield, E., Mwange, K., Meijer, M., Amend, A. S., Seifert, K. A., & Samson, R. A. (2014). *Aspergillus*, *Penicillium*, and *Talaromyces* isolated from house dust samples collected around the world. *Studies in Mycology*, 78(1), 63–139. <https://doi.org/10.1016/j.simyco.2014.07.002>
- Welsh, R. D. (2003). Zoonosis update: Sporotrichosis. *Journal of the American Veterinary Medical Association*, 223(8), 1123-1126.
- Yilmaz, N., Visagie, C. M., Houbraken, J., Frisvad, J. C., & Samson, R. A. (2014). Polyphasic taxonomy of the genus *Talaromyces*. *Studies in Mycology*, 78(1), 175–341. <https://doi.org/10.1016/j.simyco.2014.08.001>
- Zamri-Saad, M., Salmiyah, T. S., Jasni, S., Cheng, B. Y., & Basri, K. (1990). Feline sporotrichosis: An increasingly important zoonotic disease in Malaysia. *The Veterinary Record*, 127(19), 480.